Clinical Case Reports International

Clinical Image
Published: 25 May, 2022

Cardiac Arrest due to a Myocardial Mass in a Pregnant Woman

Abdullah Kaplan*[1,2,3]

[1]*Department of Cardiology, Kemer Public Hospital, Turkey*

[2]*Department of Pharmacology and Toxicology, American University of Beirut, Lebanon*

[3]*Department of Cardiovascular, American University of Beirut Medical Center, Lebanon*

Keywords

Arrhythmias; Cardiac arrest; Echocardiography; Myocardial mass; Pregnancy

Clinical Image

A 25-year-old pregnant woman was admitted to our emergency room due to loss of consciousness at home. The patient was conscious on arrival. She was pregnant with her second child and in 37th week of pregnancy. Although she had experienced palpitation many times during her pregnancy, she never lost consciousness. Shortly after her admission to the emergency room, cardiac arrest occurred, and cardiopulmonary resuscitation was started immediately. Sinus rhythm was restored following chest compression and defibrillation. Echocardiography was performed in the emergency room, and we were surprised by the unexpected image (Figures 1-5, Videos 1-4). It was a solid mass with a diameter of 4 cm in the interventricular septum. It did not cause significant dynamic obstruction at the left ventricular outflow tract (Videos 1-4). But it reduced both right and left ventricular cavity size. Although the mass consisted of hyperechogenic and circular walls, the center of it was hypoechogenic. Hemodynamic parameters of the patient were unstable. Ventricular tachycardia episodes frequently occurred, and her unborn baby was under stress. Under close hemodynamic monitoring Caesarean Section was performed within a short time. The mother was

Figure 1: Parasternal long axis view revealed the mass originated from the interventricular septum.

Figure 2: Parasternal long axis view revealed the mass originated from the interventricular septum.

OPEN ACCESS

Correspondence:
Abdullah Kaplan, Department of Cardiology, Kemer Public Hospital, Hastane Cd. No: 9, 07980 Kemer, Antalya, Turkey,
E-mail: kaplanabd@gmail.com

Received Date: *27 Apr 2022*
Accepted Date*: 19 May 2022*
Published Date*: 25 May 2022*

Citation:
Kaplan A. Cardiac Arrest due to a Myocardial Mass in a Pregnant Woman. Clin Case Rep Int. 2022; 6: 1334.

Figure 3: Modified apical four chamber views displayed hypoechogenic centre of the mass and occupied both ventricular cavities by the mass.

Figure 4: Modified apical four chamber views displayed hypoechogenic centre of the mass and occupied both ventricular cavities by the mass.

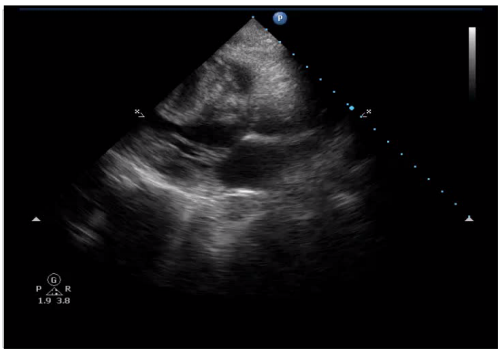

Video 1: Parasternal long axis view demonstrates the myocardial mass located in the interventricular septum.

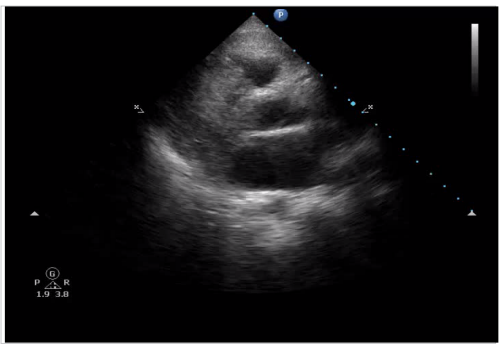

Video 2: Parasternal long axis view demonstrates the myocardial mass located in the interventricular septum.

Figure 5: Modified apical four chamber views displayed hypoechogenic centre of the mass and occupied both ventricular cavities by the mass.

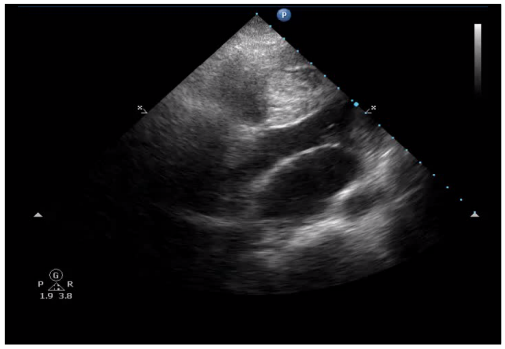

Video 3: Modified apical four chamber views shows occupied both ventricular cavities by the mass and restricted movement of mitral valve and its corda during filling phase.

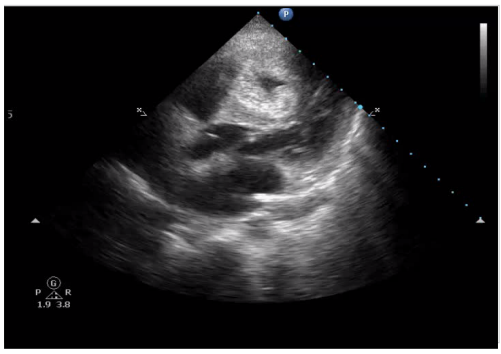

Video 4: Modified apical four chamber views shows occupied both ventricular cavities by the mass and restricted movement of mitral valve and its corda during filling phase.

referred to a tertiary centre for further investigation. But she died after hours in the intensive care unit.