



## Endovascular Treatment for Delayed Life Threatening Hemorrhage Following Tracheostomy: Our Experience in Three Patients

Ofir Zavdy<sup>1</sup>, Golda Grinblat<sup>2\*</sup>, Dan Hebron<sup>3</sup>, Isaac Shochat<sup>2</sup>, Dor Maayan<sup>2</sup>, Waseem Watad<sup>4</sup>, Mickey Dudkiewicz<sup>2,5</sup> and Itzhak Braverman<sup>2</sup>

<sup>1</sup>Department of Otolaryngology, Rabin Medical Center, Israel

<sup>2</sup>Department of Otolaryngology, Hillel Yaffe Medical Center, Israel

<sup>3</sup>Department of Diagnostic Radiology, Hillel Yaffe Medical Center, Israel

<sup>4</sup>Department of Otolaryngology, Bnai Zion Medical Center, Israel

<sup>5</sup>Hillel Yaffe Medical Center, Israel

### Abstract

Post-tracheostomy bleeding is a potentially life-threatening complication. Delayed bleeding is usually the result of a trachea-arterial fistula, most likely an innominate artery (TIAF). Although the risk for TIAF complications in tracheostomy is less than 1%, mortality rates are extremely high. Endovascular interventions are becoming more available worldwide, replacing the need for open surgery.

**Objective:** To describe our experience with endovascular treatments for immediate and delayed post-tracheostomy hemorrhage.

**Methods:** Retrospective case series of three patients, treated with an endovascular approach for delayed life-threatening hemorrhage due to vascular injuries following tracheostomies.

**Results:** Diagnostic imaging studies were performed on all patients and included CTA scans. Emergent interventional angiography was performed *via* a brachial or femoral approach with the use of stent-graft or balloon grafts. All three patients survived the procedures and were closely monitored in the intensive care unit for a few days before being discharged home.

**Conclusion:** Endovascular treatments offer high success rates and fewer complications, compared to open surgery. It is an important treatment modality for every multidisciplinary team treating post-tracheostomy hemorrhage. Only with proper teamwork, can we be able to rapidly diagnose and treat these patients, and to increase odds for survival.

**Keywords:** Bleeding; Trachea-innominate; Fistula; Endovascular; Stenting; Angiography

### Introduction

Post-tracheostomy hemorrhage is a potentially life-threatening complication that occurs in approximately 1% of cases and requires immediate intervention [1]. Iatrogenic vascular injury to the jugular and carotid vessels and branches of the neck during surgery is usually the cause for major bleedings during the immediate postoperative period, lasting up to 3 days. Delayed bleeding is usually the result of tracheal erosion by a major artery, leading to pseudoaneurysms or fistulae [2]. In most cases, the innominate artery is involved, resulting in Trachea-Innominate Artery Fistula (TIAF), with mortality rates reaching 100% [3]. In some cases, sentinel bleeding, hemoptysis, or pulsation around the cannula may precede. In the past, the only treatment options for acute and delayed bleeding were open surgery to repair, ligate or resect the damaged vessels. Once the bleeding is controlled, repair of the tracheal fistula is indicated. Reported success rates following surgical repairs are low, with high morbidity and mortality of more than 75% [4]. In recent years, an endovascular approach is replacing the need for surgery, with higher survival rates of over 70% and fewer complications [5]. We sought to describe our experience with endovascular treatments for immediate and delayed post-tracheostomy hemorrhage.

### OPEN ACCESS

#### \*Correspondence:

Golda Grinblat, Department of Otolaryngology, Hillel Yaffe Medical Center, Hadera, Haifa, Israel, E-mail: goldagrblatmd@gmail.com

Received Date: 24 Feb 2022

Accepted Date: 15 Mar 2022

Published Date: 25 Mar 2022

#### Citation:

Zavdy O, Grinblat G, Hebron D, Shochat I, Maayan D, Watad W, et al. Endovascular Treatment for Delayed Life Threatening Hemorrhage Following Tracheostomy: Our Experience in Three Patients. *Clin Case Rep Int.* 2022; 6: 1302.

**Copyright** © 2022 Golda Grinblat. This is an open access article distributed under the Creative Commons Attribution License, which permits unrestricted use, distribution, and reproduction in any medium, provided the original work is properly cited.

## Methods

The Strengthening the Reporting of Observational Studies in Epidemiology (STROBE) guidelines for reporting observational studies and the Case Report (CARE) guidelines were followed in the study.

### Design and settings

After receiving the Institution Review Board (IRB) approval, a retrospective chart review was conducted. Three patients who were treated for acute life-threatening post-tracheostomy bleeding with endovascular stenting during 2014 to 2016 qualified.

### Participants

All patients were admitted to the Emergency Department (ED) after stomal bleeding had already commenced at home and were treated in a single medical center with a multidisciplinary team of professionals from head and neck surgery, vascular surgery, and Interventional Radiology (IR) departments. Diagnostic imaging studies were performed on all patients and included CTA scans. Follow-up period was of up to one year with no evidence of recurrent bleeding in any of presented patients.

### Interventional angiography

Emergent interventional angiography was performed through a 10Fr. sheath via a brachial or femoral approach. Stent grafts were used in all patients (Bard Fluency, C. R. Bard, Inc. New Jersey, USA), with the additional use of a balloon expandable stent (Medtronic Assurant Cobalt, Medtronic Inc. Minneapolis, USA) in some. After the procedure, patients were closely monitored in the Intensive Care Unit (ICU) for several days before being discharged home.

### Brief patient presentations and clinical findings

**Patient A:** A 72-year-old male with ischemic heart disease treated with a coronary bypass 5 years ago, developed acute pulmonary edema and respiratory distress due to severe aortic stenosis. He was intubated and later underwent tracheostomy. On the 40<sup>th</sup> day following surgery (POD 40), the patient presented to the Emergency Department (ED) with an active bleeding exiting the stomal area. Immediately upon arrival to the hospital the tracheostomy cuff was inflated. The patient was rushed to CTA, followed by an urgent diagnostic angiography in the IR unit. A large right subclavian artery pseudoaneurysm was detected (Figures 1A-1C). Through a 10Fr. sheath right brachial artery approach, three stent grafts sized 12 mm to 13.5 mm, were placed in an overlapping manner. Next, a 10mm balloon expandable stent was placed in the subclavian artery origin, followed by remodeling with 12 mm balloon inflation. The patient was then transferred to the ICU and was discharged after a week.

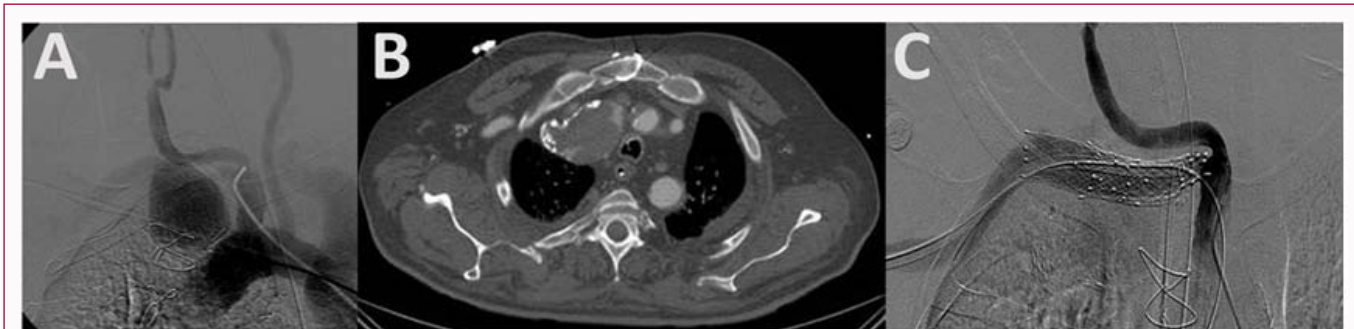No complications due to the angiography were seen. Six months following the procedure, the patient remained asymptomatic.

**Patient B:** A 75-year-old woman was brought to the ED following a sentinel bleeding from the tracheostomy cannula. She had been put on assisted ventilation and underwent tracheostomy 3 months prior due to a right-sided hemisphere stroke. Upon arrival to the ED, acute intractable bleeding begun. The patient was immediately transferred to the Operating Room (OR), for laryngotracheoscopy. During the procedure the bleeding had already stopped, and the origin was not traced. She was then transferred to CTA, which demonstrated the source of the bleeding from a TIAF (Figure 2). The patient was rushed to the IR unit, where a 12 mm stent graft was inserted to the innominate and subclavian arteries, covering the right common carotid artery origin, through a 10Fr. sheath right brachial approach. A control of the bleeding was achieved. As the patient had already suffered from a right sided stroke, no sequela following the procedure was seen. A post procedural CTA demonstrated accurate stent position without evidence of residual bleeding. In the ICU the patient had undergone a successful cardiac resuscitation following an arrest, due to significant blood loss. The patient was weaned from mechanical ventilation 3 days after the procedure. On follow-up, 9 months after the incident, she remained asymptomatic.

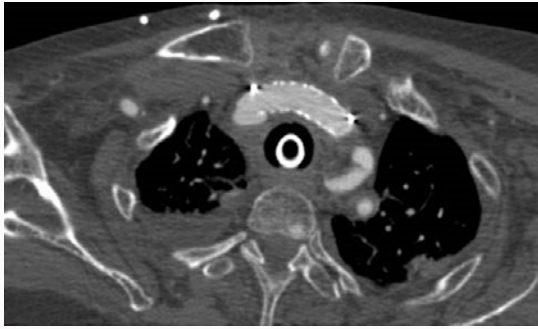
**Patient C:** An 80-year-old woman presented had undergone tracheostomy following prolonged intubation 8 months ago. She was admitted to the ED due to acute and significant bleeding from the stomal area. Hemostasis was achieved by inflating the tracheostomy balloon and local dressing pressure. An emergency angiography demonstrated TIAF (Figure 3A, 3B). Through a 10Fr. sheath right femoral approach, a 13.5 mm stent graft was placed in the innominate artery, followed by 14 mm balloon inflation. Control of the bleeding was achieved. The patient was discharged from the ICU after a week. On one year follow-up the patient remained asymptomatic.

## Discussion

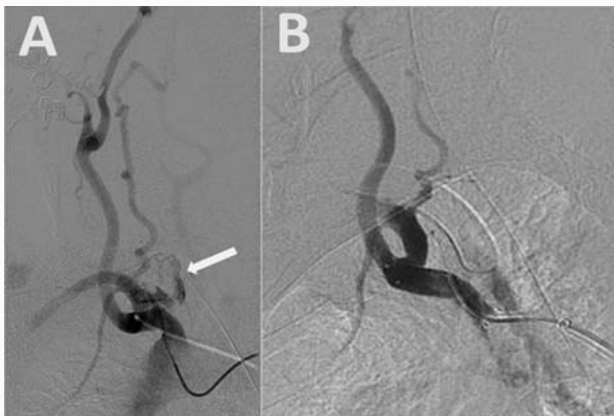
Any significant bleeding following tracheostomy, either immediate or delayed is a potential life-threatening complication. Peak incidence and the risk for bleeding are found during the first 6 weeks after surgery [6]. Most of delayed postoperative bleedings are the result of TIAF and in more than 50% of cases, a sentinel bleeding occurs. Risk factors associated with an increased risk for TIAF are low tracheal ring incisions (lower than 3<sup>rd</sup> ring), which lead to cannula-induced constant arterial pressure, surgical site infection and overinflated cuff that can cause pressure necrosis to the tracheal wall [6]. Following angiography, all three patients survived the procedures, without re-interventions. No neurological sequela was



**Figure 1:** A). Large pseudoaneurysm arising from right subclavian artery demonstrated by conventional angiography and after treatment: B). As seen in CTA and C). As seen in conventional angiography.



**Figure 2:** Post-treatment CTA image demonstrating stent-graft in the innominate artery, with no residual bleeding.



**Figure 3:** A). Active bleeding from an innominate artery, demonstrated in conventional angiography (arrow). B). Post-treatment.

seen. Follow-up period was of up to one year with no evidence of recurrent bleeding in any of presented patients.

Surgery to control early and delayed postoperative bleeding in general, and specifically in cases of TIAF, is still considered the treatment of choice. Ligation or resection of the innominate artery and repair of the fistula is usually performed via a median sternotomy approach, with the use of grafts if needed [7]. Complications following surgery include cerebral hypoperfusion that may lead to stroke, graft infection, high risks of re-bleeding and poor survival rates. Wang et al. [8] reported a 7% 1-year survival rate following a surgical TIAF repair [8].

Taechariyakul et al. [9] published in a recent literature review of 260 cases, a comparison between surgical and endovascular interventions for TIAF. Endovascular approach was associated with significantly lower complication rate of 30%, compared to 50% in open surgery. Significantly lower 30-day mortality rate of 9% in endovascular approach was also seen, compared to 23% in open surgery [9].

In a recently published systematic review by O'malley et al. [10] covering 27 patients who underwent endovascular interventions for

TIAF, 23% of patients were hemodynamically unstable, and 96% were treated with stent grafts. They reported re-bleeding in 19% of patients, that required re-intervention, and rescue sternotomy in 11%. Overall mortality rate was 30% [10]. Our results support the use of endovascular treatments for post-tracheostomy bleeding, as a safe alternative to surgery, and further contribute to the growing body of evidence published in the literature.

## Conclusion

Post tracheostomy bleeding, either acute or delayed, is a life-threatening complication that require prompt diagnosis, as well as immediate assessment for respiratory and hemodynamically instability in the patient. A multidisciplinary teamwork is needed to decide on the proper treatment in each patient, to maximize the odds for survival. In an era of bursting technological advancement, endovascular treatments offer high success rates and fewer complications, compared to open surgery.

## Authorship Statement

Each author has made substantial contributions to the conception or design of the study, the acquisition of data, analysis of the results and the process of drafting, revising, and approving the final version.

## References

1. Epstein SK. Late complications of tracheostomy. *Respir Care.* 2005;50(4):542-9.
2. Goldenberg D, Ari EG, Golz A, Danino J, Netzer A, Joachims HZ. Tracheostomy complications: A retrospective study of 1130 cases. *Otolaryngol Head Neck Surg.* 2000;123(4):495-500.
3. Scalise P, Prunk SR, Healy D, Votto J. The incidence of tracheo-arterial fistula in patients with chronic tracheostomy tubes: A retrospective of 544 patients in a long-term facility. *Chest.* 2005;128(6):3906-9.
4. Allan JS, Wright CD. Tracheoinnominate fistula: Diagnosis and management. *Chest Surg Clin N Am.* 2003;13(2):331-41.
5. Deguchi J, Furuya T, Tanaka N, Nobori N, Seki Y, Nomura Y, et al. Successful management of tracheo-innominate artery fistula with endovascular stent graft repair. *J Vasc Surg.* 2001;33(6):1280-2.
6. Nakai M, Sato H, Sato M, Ikoma A, Sanda H, Nakata K, et al. Tracheo-innominate artery fistula successfully treated by endovascular stent-graft repair. *Jpn J Radiol.* 2013;31(1):65-70.
7. Wright, CD. Management of tracheoinnominate artery fistula. *Chest Surg Clin N Am.* 1996;6(4):865-73.
8. Wang XL, Xu ZG, Tang PZ, Yu Y. Tracheo-innominate artery fistula: Diagnosis and surgical management. *Head Neck.* 2013;35(12):1713-8.
9. Taechariyakul T, Keller FS, Jahangiri Y. Endovascular treatment of tracheoinnominate artery fistula: Case report and literature review with pooled cohort analysis. *Semin Thorac Cardiovasc Surg.* 2020;32(1):77-84.
10. O'Malley TJ, Jordan AM, Prochno KW, Saxena A, Maynes EJ, Ferrell B, et al. Evaluation of endovascular intervention for tracheo-innominate artery fistula: A systematic review. *Vasc Endovascular Surg.* 2021;55(4):317-24.