



## Localized Scleroderma vs. Overlap Syndrome

Alice Azoicai\*

Department of Pediatrics, Grigore T. Popa University of Medicine and Pharmacy, Romania

### Background

Scleroderma is a rare, autoimmune, chronic condition that affects the connective tissue by excessive collagen production. Juvenile localized scleroderma (morphea) is the predominant scleroderma in childhood which affects the skin and may extend to the underlying fascia, muscle, joints and bone, causing the loss of the mobility and, sometimes, development towards systemic sclerosis [1,2].

### Case Presentation

The authors present a 7 years-old-girl admitted for investigation of an atrophic linear lesion that appeared approximately 4 months prior to the time of the admission onto the left palm and fingers of the left hand. In time, the lesion extended upwards, reaching the left axillary area and the left side of the neck. Furthermore, the child lost the mobility and flexibility of the 5<sup>th</sup> and 4<sup>th</sup> left finger (Figure 1).

**Personal history** doesn't reveal any specific or suggestive illness until the lesion appeared. However, she was diagnosed with GERD in early childhood, and the symptoms still appear inconstantly.

**Family history**- her father had a stroke at 34 years, with transient immobility of the upper and lower left limb (no medical records for a specific diagnosis), and her 33 years old mother is diagnosed with C and S protein deficiency (early after she gave birth to the child). She also has a healthy 10 years-old sister. Within her mother's family tree there is also a high burden of autoimmunity disorders (type 1 diabetes in a cousin, an aunt with autoimmune thyroiditis).

**The clinical examination** is with a good general status, but with paleness, enlarged tonsils, normal cardiovascular and respiratory auscultation, HR=88/min, RR=20/min, BP=110/50 mmHg, normal stools and urine output, normal neuropsychological development, no signs of neural or ocular impairment [3,4].

### Biological Findings

Normal CBC and eosinophil count, ESR, CRP, normal CK, slightly elevated gammaglobulins (17%), normal rheumatoid factor, normal IgA, M, G and normal thyroid hormone levels.

Normal biochemical parameters, normal urinalysis, normal Addis test.

Elevation of dsDNA antibodies, normal ANA, normal anticentromer and SCL70 antibodies

**The skin biopsy** revealed specific anatomical macroscopical and microscopical changes within

### OPEN ACCESS

#### \*Correspondence:

Alice Azoicai, Department of Pediatrics,  
Grigore T. Popa University of Medicine  
and Pharmacy, Iași, Romania,  
E-mail: doina.azoicai@gmail.com

Received Date: 08 Mar 2022

Accepted Date: 04 Apr 2022

Published Date: 08 Apr 2022

#### Citation:

Azoicai A. Localized Scleroderma vs.  
Overlap Syndrome. *Clin Case Rep Int.*  
2022; 6: 1307.

Copyright © 2022 Alice Azoicai. This is an open access article distributed under the Creative Commons Attribution License, which permits unrestricted use, distribution, and reproduction in any medium, provided the original work is properly cited.

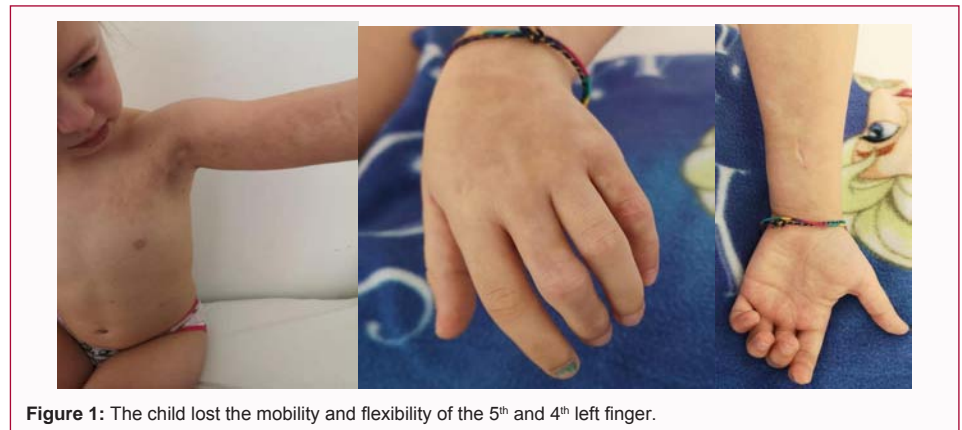

Figure 1: The child lost the mobility and flexibility of the 5<sup>th</sup> and 4<sup>th</sup> left finger.

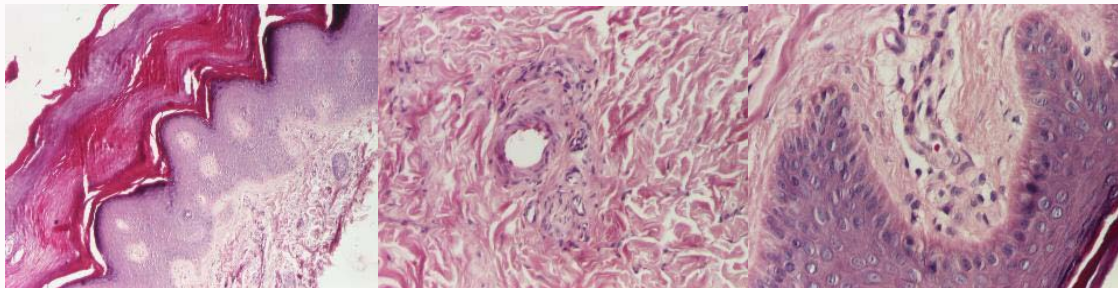


Figure 2: EEG, EKG, normal cardiac and abdominal ultrasound.

the three layers, such as:

- Sharply squared-off biopsy ('cookie-cutter' sign)
- Atrophic epidermis
- Thickened, hyalinized collagen, with possible loss of appendageal structures (sweat glands and hair follicles)
- Fat loss/entrapment
- Inflammatory cell infiltrate (lymphocytes + plasma cells).

She performed also a normal EEG, EKG, normal cardiac and abdominal ultrasound (Figure 2).

## Treatment

The patient received immunosuppressive therapy- topic, oral and parenteral corticosteroids, with mild response regarding the extension and the global aspect of the lesions. Topic tacrolimus was recommended for the skin atrophic area, but the parents refused for the moment the therapy, due to fear of possible teratogenic side-effects.

Methotrexate was the second therapeutic approach, being initialized only two weeks before the current communication, with no complication or side-effect until this time.

## Assessing the Severity of the Disease (The LoSCAT Instrument)

The *LoSCAT* assesses 18 cutaneous anatomic sites, capturing both disease activity (*mLoSSI*) and damage (*LoSDI*) parameters. Scores for each site are based on the most severe score for each parameter. In order to minimize inter-subject variability, all skin changes are compared with the contralateral or ipsilateral skin area. The *mLoSSI* includes the sums of 3 separate activity scores as follows: (1) Erythema (ER): 0: No erythema; 1: Slight erythema/pink; 2: Red/clearly erythema; and 3: Dark red or marked erythema/violaceous. (2) Skin thickness (ST): 0: Normal skin thickness and freely mobile; 1: Mild increase of thickness, mobile; 2: Moderate increase of thickness; impaired skin mobility; 3: Marked increase of thickness or no mobility of skin. (3) New lesion/lesion extension (N/E): New lesion development and/or enlargement of an existing lesion within the past month (score of 3). Three cutaneous damage domains are summated to obtain the *LoSDI*, as follows: (1) Dermal atrophy (DAT): 0: Normal skin; 1: Mild skin atrophy, shiny skin; 2: Moderate atrophy, visible blood vessels or mild 'cliff-drop' sign; and 3: Severe skin atrophy, obvious 'cliff-

drop' sign. (2) Subcutaneous atrophy (SAT): 0: Normal subcutaneous thickness; 1: Flattening or 1/3 fat loss; 2: Obvious concave surface or 1/3-2/3 fat loss; and 3: Severe subcutaneous fat loss (>2/3 loss). (3) Dyspigmentation (DP): Assessing both hyper- or hypopigmentation, whichever is most prominent: 0: Normal skin pigment, 1: Mild; 2: Moderate; and 3: Severe depigmentation [5,6].

Patient's disease activity level was 4, and the cutaneous damage level was assessed at 6 for the second time that she presented for follow-up, having daily corticoid oral therapy and parenteral administration of high-dose corticosteroid during the first hospitalization [7].

## Conclusion

Localized scleroderma typically presents in childhood and it can cause severe physical deformity and corresponding emotional effects. Despite being called a 'localized' disease, approximately one quarter of the patients have comorbidity, including orthopedic, neurologic, ocular, and other autoimmune conditions. In this particular case (autoimmune disease within the family, elevated dsDNA antibodies), the discussion is open regarding the possibility of the onset of an Overlap syndrome.

## References

1. Zulian F, Lanzoni G, Castaldi B. Systemic sclerosis sine scleroderma in children. *Rheumatology (Oxford)*. 2021;keab738.
2. Stevens AM, Torok KS, Li SC, Taber SF, Lu TT, Zulian F. Immunopathogenesis of juvenile systemic sclerosis. *Front Immunol*. 2019;10:1352.
3. Kelsey CE, Torok KS. The localized scleroderma cutaneous assessment tool: Responsiveness to change in a pediatric clinical population. *J Am Acad Dermatol*. 2013;69(2):214-20.
4. Zulian F, Vallongo C, Woo P, Russo R, Ruperto N, Harper J, et al. Localized scleroderma in childhood is not just a skin disease. *Arthritis Rheum*. 2005;52:2873-81.
5. Zulian F, Athreya BH, Laxer R, Nelson AM, de Oliveira SKF, Punaro MG, et al. Juvenile localized scleroderma: Clinical and epidemiological features in 750 children. An international study. *Rheumatology (Oxford)*. 2006;45(5):614-20.
6. Murray KJ, Laxer RM. Scleroderma in children and adolescents. *Rheum Dis Clin North Am*. 2002;28:603-24.
7. Uziel Y, Krafchik BR, Silverman ED, Thorner PS, Laxer RM. Localized scleroderma in childhood: A report of 30 cases. *Semin Arthritis Rheum*. 1994;23:328-40.