



Removal of a Bent Tibial Intramedullary Nail: A Case Report and a Review of the Literature

Gaubert L and Breda R*

Department of Orthopedics and Trauma Surgery, HIA Sainte-Anne, France

Abstract

Intramedullary nailing is the gold standard for the management of tibia fractures. The possible removal of the material can be considered at a distance from the pose. The 18-month period is commonly used as the minimum date on which this extraction can be considered.

The recurrence of trauma on a tibia with existing osteosynthesis equipment may induce rare but serious complications such as deformity or rupture. Sometimes, the importance of the deformity is at the origin of vascular complications, imposing an urgent surgery as this clinical case shows.

A 25-year-old patient was involved in a high kinetic road accident. The lesion showed an open fracture on a centromedullary nail of the right leg with an irreducible deformation at 45° lateral flexion at the 1/3 mid-1/3 lower junction. He presented a vascular lesion with a weak distal pulse.

We opted for an anterolateral abord with corticotomy to remove the nail by antegrade extraction. Secondly, we performed plate osteosynthesis in a conventional manner.

The presence of osteosynthesis equipment can expose to complications in case of trauma as illustrated in this clinical case. It seems that a complication to this degree of severity is infrequent in the literature. Ablation of osteosynthesis equipment must be included in the therapeutic project, particularly in a population at high risk of trauma.

Keywords: Centromedullary Nail; Removal; Complication

Introduction

Intramedullary nailing is the gold standard for the management of tibia fractures [1,2]. Consolidation is achieved in the vast majority of cases. The possible removal of the material can be considered at a distance from the installation. The 18-month period is commonly used as the minimum date at which this extraction can be considered [3].

Traumatic deformity is very rare. This deformation can cause a rupture of the material and making its extraction complicated. The extraction of a broken nail has been described by many authors and there are many methods, some of which are original [4].

The extraction of a deformed nail is an exceptional case and requires a reflection on the surgical strategy [5]. Sometimes, the importance of the deformity is at the origin of vascular complications, imposing an urgent surgery.

Case Presentation

A 25-year-old patient was cared for following an accident involving high kinetic motorcycles at the Army Instruction Hospital (HIA) of the Sainte-Anne in Toulon. The initial assessment showed a hemodynamically stable patient.

The primary evaluation showed an irreducible deformity of the right leg at 45° lateral flexion and about 10 degrees in frontal flexion at the junction 1/3 mid-1/3 inferior of the tibia (Figure 1-4). A cutaneous opening of a few centimeters was at the level of flexion. The clinical examination found a vascular suffering with a weak distal pulse, compared to the healthy side.

The surgical strategy had to meet several objectives. It had to allow ablation nail to allow aligning the limb. It had to preserve the bone capital to allow a secondary osteosynthesis. We decided to perform an anteromedial approach with a distal tibial corticotomy flap respecting the tibio-talar joint and an economical corticotomy at its proximal part. This is to extract the nail retrograde way (Figure 5,6).

OPEN ACCESS

*Correspondence:

Renaud Breda, Department of Orthopedics and Trauma Surgery, HIA Sainte-Anne, 83008 Toulon, France, E-mail: renaudbreda@yahoo.fr

Received Date: 01 Mar 2019

Accepted Date: 20 Mar 2019

Published Date: 25 Mar 2019

Citation:

Gaubert L, Breda R. Removal of a Bent Tibial Intramedullary Nail: A Case Report and a Review of the Literature. Clin Case Rep Int. 2019; 3: 1097.

Copyright © 2019 Breda R. This is an open access article distributed under the Creative Commons Attribution License, which permits unrestricted use, distribution, and reproduction in any medium, provided the original work is properly cited.

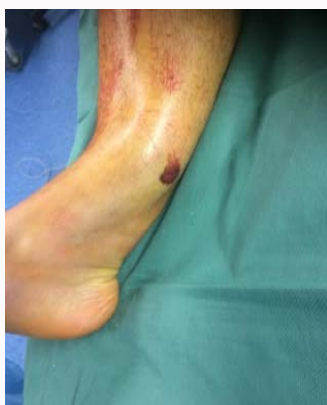

Figure 1: Irreducible deformity of the right leg.

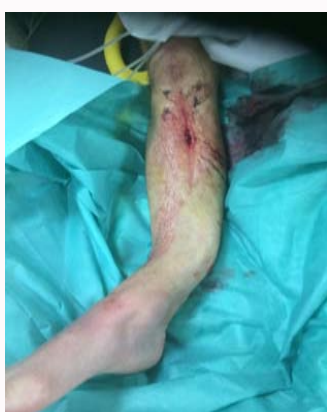

Figure 2: Irreducible deformity of the right leg at 45°.

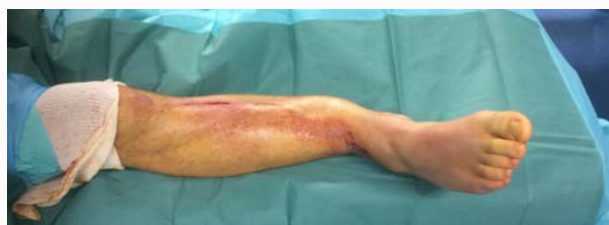

Figure 3: Irreducible deformity of the right leg at 45° lateral flexion.

With regard to osteosynthesis, we have been able to perform a conventional osteosynthesis by medial distal tibial plate LCP 3.5 (Figure 7,8).

Discussion

The deformation of osteosynthesis material is frequent in cases of nonunion due to a progressive and irreversible embrittlement of the metal. In the vast majority of cases, the diagnosis is made at the time of the rupture of the latter and the extraction of this material is carried out in semi emergency. There are many methods of extraction [6]. The authors focus mainly on tactics with proximal anterograde extraction and distal percutaneous or retrograde extraction. In all clinical cases reported, there is no simple deformation but a complete rupture of the metallic material [4,7].

The deformation of material in traumatic cases is much less frequent [7]. The extraction of the material is made very complicated by this deformation. Yip et al. reported extraction of two tibial nails

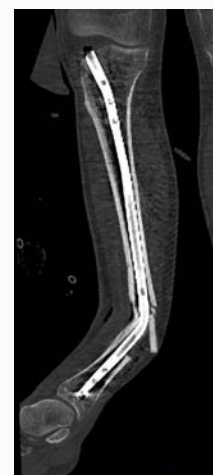


Figure 4: Frontal flexion at the junction 1/3 mid-1/3 inferior of the tibia.

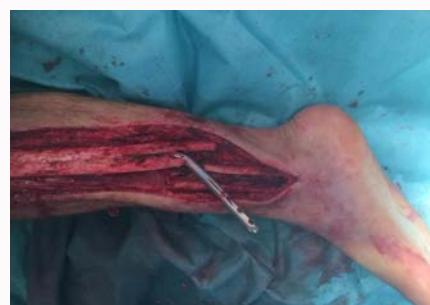

Figure 5: Nail retrograde way.

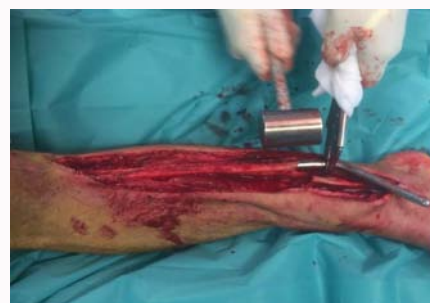

Figure 6: Anteromedial approach with a distal tibial corticotomy flap.

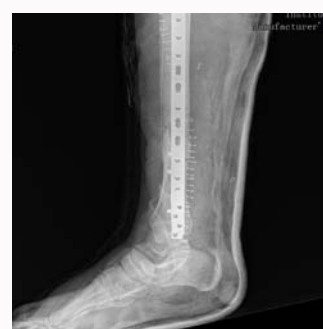

Figure 7: Conventional osteosynthesis.

by standard route [8]. By carefully studying the deformations, one realizes that these were not important and finally allowed a classic extraction of the nail. One case reported by these authors had 13° of

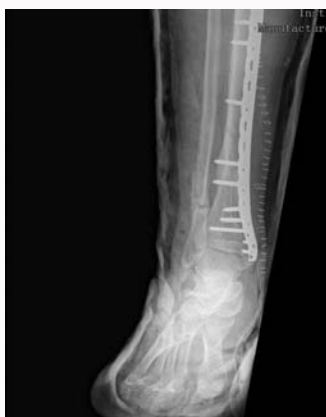

Figure 8: Medial distal tibial plate LCP 3.5.

anterior flexion and 20° of valgus. Our clinical case had a much larger deformity.

The idea of deforming the tibia by an external force to obtain a realignment allowing the conventional extraction of the nail has not been seriously considered. Some authors have tried with total failure [7].

Some authors propose a minimal approach on the deformation focus [9]. The goal is to cut the nail with a plier or saw. Thus, one can realign the limb and proceed to the extraction as in the case of a rupture on a nonunion. Some authors believe that the use of a saw is not advisable because of metal chips and the risk of bone burns [7].

We decided preoperatively to perform a distal corticotomy. We were then able to seize the nail to carry out a retrograde extraction. All the proximal diaphysis was intact. The bony hood was then rested and fixed by a provisional strapping and a very long bone plate was placed [10].

In conclusion, the presence of osteosynthesis equipment may expose to complications in case of trauma as illustrated by our clinical case. However, it seems that a complication at this degree of severity is exceptional in the literature. According to our service habits, the removal of osteosynthesis equipment must be included in the therapeutic project from initial management, particularly in a population at high risk of trauma.

References

1. Bhandari M, Schemitsch E, Jonsson A, Zlowodzki M, Haidukewych GJ. Gamma nail revisited: gamma nails versus compression hip screws in the management of intertrochanteric fractures of the hip: a meta-analysis. *J Orthop Trauma*. 2009;23:460-4.
2. Ehlinger M, Adam P, Bonnomet F. Fracture de l'extrémité supérieure du fémur de l'adulte. EMC-appareil locomoteur. 2014;9(2):1-18.
3. Müller ME, Allgöwer M, Schneider R, Willenegger H. Metal removal. In: Allgöwer M, editor. *Manual of internal fixation*. 3rd edn. Berlin: Springer-Verlag; 1995. p. 424.
4. Man CH, Bae MW. Method for removing broken proximal femoral nails using existing screw hole. *Acta Orthop Bras*. 2018;26(1):72-4.
5. Bewster NT, Ashcroft GP, Scotland TR. Extraction of broken intramedullary nails-an improvement in technique. *Injury*. 1995;26(4):286.
6. Al Maleh AA, Nielsen KS. How to remove a bent intramedullary nail. A technical note. *Acta Orthop Scand*. 1998;69(6):638-9.
7. Aggerwal S, Soni A, Saini UC, Gahlot N. Removal of a bent tibial intramedullary nail: a rare case report and a review of the literature. *Chin J Traumatol*. 2011;14(2):107-110.
8. Yip KM, Leung KS. Treatment of deformed tibial intramedullary nail: report of two cases. *J Orthop Trauma*. 1996; 10(8):580-3.
9. Apivatthakakul T, Chiewchantanakit S. Percutaneous removal of a bent intramedullary nail. *Injury* 2001;32(9):725-6.
10. Removal of internal fixation devices J.-C. BEL (1)(1) Service de chirurgie orthopédique et traumatologique (Pr G. Herzberg), SOFCOT 2015.