Clinical Case Reports International

Case Report
Published: 14 Feb, 2022

Rapid Bilateral Visual Loss as the Initial Clinical Manifestation in Idiopathic Hypertrophic Cranial Pachymeningitis

Shao W, Tian C, Gao L, Cui B and Shi Q*

Department of Ophthalmology, the Third Medical Center of PLA General Hospital, China

Abstract

Purpose: To describe a patient presented rapid bilateral visual loss as the initial clinical manifestation in idiopathic hypertrophic cranial pachymeningitis.

Case Report: A 59-year-old male patient presented with 4-day acute painless bilateral visual loss, with no headache, eye distension, photophobia, lacrimation or diplopia. Upon examination, the Best-Corrected Visual Acuity (BCVA) of the right eye was Hand Movement (HM), and the left eye demonstrated nothing in Light (NIL). The pupils of both eyes were round, the pupil diameter of the right eye was 2.5 mm, and that of the left was approximately 5 mm. More, the right eye showed a Relative Afferent Pupillary Defect (RAPD), and both the direct and indirect light reflexes of the left eye had disappeared. Other examinations including Color fundus, macula and optic disc photography and laboratory tests were negative. Imaging tests, including Magnetic Resonance Enhancement Imaging (MRI) were performed with dural enhancement along the floor of the anterior fossa. The patient was considered to have Idiopathic Hypertrophic Cranial Pachymeningitis (IHCP) based on laboratory tests and MRI data. After implosive treatment with hormones, the visual acuity of the patient obviously improved.

Conclusion: IHCP is a chronic inflammatory disorder characterized by diffuse thickening of the dura. A few patients present with bilateral or unilateral moderate visual loss. We report the case of an IHCP patient who presented with sharp bilateral visual loss as the initial clinical symptom, without any other typical positive manifestations. To our knowledge, this is a rarely reported case about IHCP disease.

Keywords: Idiopathic hypertrophic cranial pachymeningitis; Visual loss; Dural thickening

OPEN ACCESS

Correspondence:
Weiyang Shao, Department of Ophthalmology, the Third Medical Center of PLA General Hospital, Beijing, 100048, China, Tel: +86 010 66951286;
E-mail: weiyang_shao@163.com

Received Date: *24 Jan 2022*
Accepted Date*: 08 Feb 2022*
Published Date*: 14 Feb 2022*

Citation:
Shao W, Tian C, Gao L, Cui B, Shi Q. Rapid Bilateral Visual Loss as the Initial Clinical Manifestation in Idiopathic Hypertrophic Cranial Pachymeningitis. Clin Case Rep Int. 2022; 6: 1284.

Introduction

Idiopathic Hypertrophic Cranial Pachymeningitis (IHCP) is a rare fibrosing inflammatory disorder characterized by thickening of the dura matter at the base of the skull, tentorium and falx. The clinical manifestations include chronic headache, cranial nerves affected and epilepsy, a few patients present with bilateral or unilateral moderate visual loss. We describe the case of a patient who presented with bilateral visual loss without any other positive manifestations; the patient was initially diagnosed with Ischemic Optic Neuropathy (ION), but further investigation revealed IHCP. This study was approved by the ethics committee of the 6th Medical Centre of Chinese People's Liberation Army General Hospital. Written informed consent forms were obtained from the patient, who gave his consent that findings and images about himself were published in the journal and associated publications.

Case Presentation

A 59-year-old male patient presented with 4-day acute painless bilateral visual loss, with no headache, eye distension, photophobia, lacrimation or diplopia. The patient denied a history of diabetes, hypertension, coronary heart disease or auto-immune disease. Of note, ION diagnosis was considered, and medical cared such as intramuscular injection of mouse nerve growth factor prior to hospitalization did not result in visual recovery.

Upon examination, the Best-Corrected Visual Acuity (BCVA) of the right eye was Hand Movement (HM), and the left eye demonstrated nothing in Light (NIL). The pupils of both eyes were round, the pupil diameter of the right eye was 2.5 mm, and that of the left was approximately 5

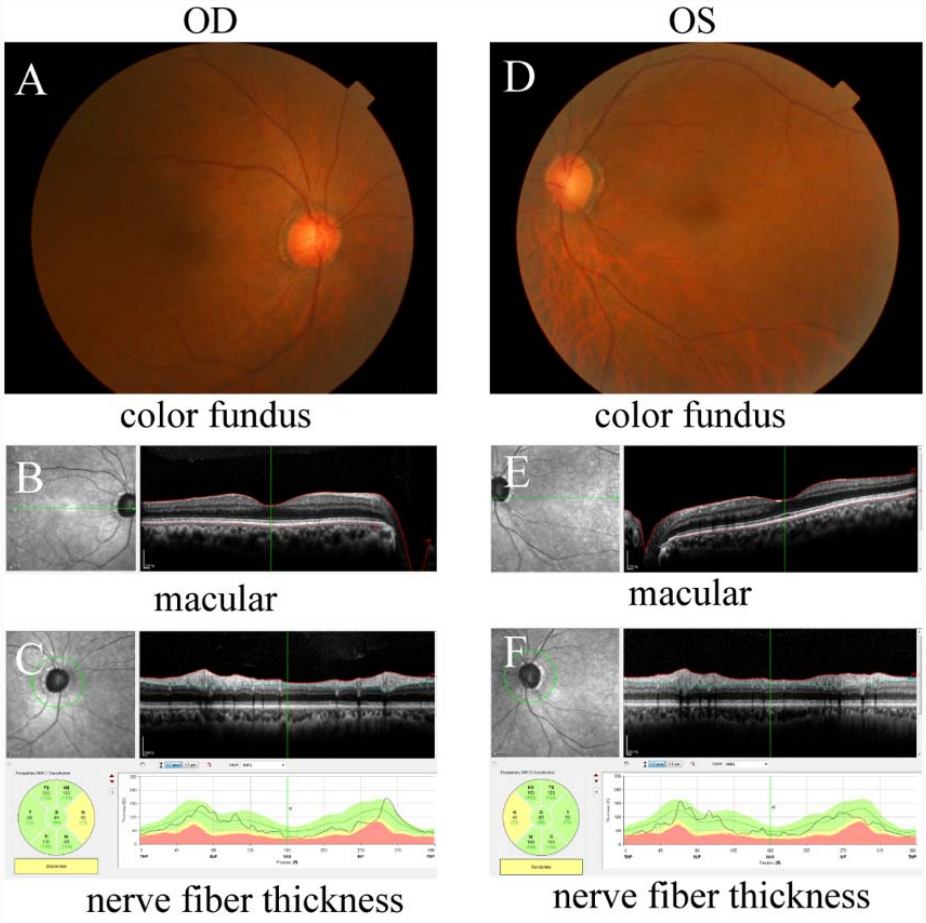

Figure 1: Color fundus, Optical Coherence Tomography (OCT) of the macula and optic disc photography of the right eye (OD) and left eye (OS) before treatment. (A-C): right eye, (D-F) left eye.

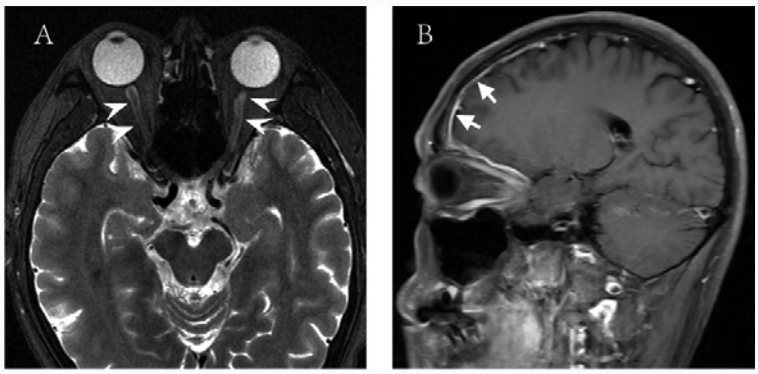

Figure 2: MRI brain of the patient after gadolinium contrast administration showing optic nerves myelin enhanced (A) and There is diffuse smooth enhancement of the pachymeninges (B) eyeballs and cortex of brain are normal in their size, shape, and signal intensity. Bilateral enhancement of posterior intraconal optic nerve sheath with normal signal intensity of optic nerves.

mm. More, the right eye showed a Relative Afferent Pupillary Defect (RAPD), and both the direct and indirect light reflexes of the left eye had disappeared. Other examinations including color fundus photography, Optical Coherence Tomography (OCT) of the macula and optic disc photography of the right and left eye were normal (Figure 1).

Laboratory tests showed that the C-Reactive Protein (CRP) level was 13.1 mg/L (reference value: 0 mg/L to 8 mg/L), and the Erythrocyte Sedimentation Rate (ESR) was 72 mm/h (reference value: 0-15). The results of other tests including routine blood, urine routine, blood biochemistry, antinuclear antibody, tuberculosis antibody, *Mycobacterium tuberculosis* γ interferon, syphilis serum antibody, tumor screening, TORCH antibody, IgG4 antibody, and thyroid function tests were normal. The results of routine cerebrospinal fluid, biochemistry, cytology, anti-ganglioside anti-antibody, and aquaporin 4 tests were also normal. The results of other tests such as fluid tests to check for bacteria, fungi, *Cryptococcus neoformans*, and acid-fast bacilli were also negative. Imaging tests, including Magnetic Resonance Imaging (MRI) with gadolinium contrast, were performed

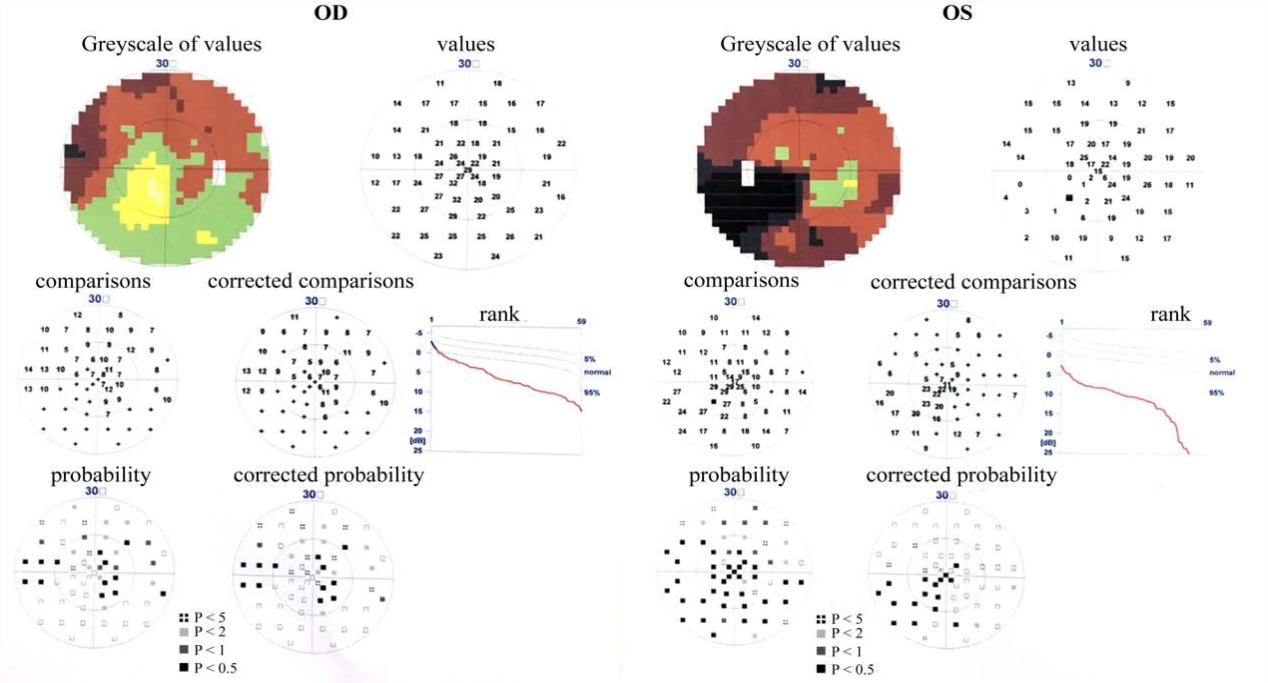

Figure 3: Visual field examination of right eye (OD) and left eye (OS) after 20 days treatment. Right eye showed superior altitudinal visual acuity was obviously decreased; left eye showed that one-quarter of the visual field was completely defected.

with dural enhancement along the floor of the anterior fossa, with the brain sickle visible, especially on the left side (Figure 2). The cavernous sinus and temporal lobe demonstrated possible aggressive signals. No significant high signal was found with diffusion-weighted imaging. In summary, the patient was considered to have IHCP based on laboratory tests and MRI data. Treatment with methylprednisolone *via* intravenous drip infusion was continued, followed by oral prednisone acetate tablets. Twenty days after treatment, the BCVA of the patient was significantly restored: that of the right eye reached 20/20, and that of the left eye was 20/200. Unfortunately, visual field examination showed that the visual light sensitivity in the right eye had decreased, and examination of the left eye showed that one-quarter of the visual field was completely loss (Figure 3).

Discussion

Hypertrophic Pachymeningitis (HP) is a chronic inflammatory disorder characterized by fibrous thickening of the cerebral and/or spinal dural mater [1]. HP is divided into two types, Idiopathic Hypertrophic Pachymeningitis (IHP), for which no identifiable cause has been found, and secondary HP, for which is described in association with trauma, infections, tumors, autoimmune/inflammatory diseases, and cerebrospinal fluid hypotension syndrome. IHCP, the most common features of which is chronic intermittent headache, can also be expressed as cephalagra, local or whole brain blunt pain, or progressive palsy of cranial nerves [2]. One important reason for the ease of cranial nerve damage is the narrowing of the skull gap, in which cranial nerves pass, due to endocranial hypertrophy. The thickened dura might invade the oculomotor nerve, abductor nerve, trochlear nerve, trigeminal nerve and optic nerve [3]. Severe injury of the optic nerve alone occurs infrequently but can lead to painless rapid bilateral visual loss. Mathew et al. [4], reported one case of IHCP presenting as acute left-sided painless visual loss, and the patient complained of persistent left-sided headache and numbness on her forehead in the past few years [4]. Our case presented as rapid bilateral visual loss as the initial clinical manifestation, and we have not found similar previous reports.

The diagnosis of IHCP can be made by combining clinical manifestations, imaging examination results, laboratory test results and pathological features. The pathological characteristics are diffuse fibrous hypertrophy of the dura matter and lymphocytes as well as plasma cell infiltration; IHCP can also present with glass-like changes or caseous necrosis. It can also be observed on MRI and defined pathologically on biopsy; the performance of MRI was correlated with the clinical state in 80% of cases [5]. Imaging demonstrated the diffuse thickening of the dura; the lesions appeared hypointense or isointense on T1-weighted sequences and hypointense on T2-weighted sequences. The scope of the dura was larger on gadopentetate-enhanced T1-weighted sequences than on plain scans [6]. According to others, laboratory findings might show increased ESR or CRP levels in patients, and some patients show positive results for auto antibodies including ANA, P-ANCA, ACA and RF [7,8].

Conclusion

Intracranial neuropathy might occur rapidly and progressively, and the damage is difficult to recover. A clear and correct diagnosis as soon as possible and timely treatment are critical. In this report, the visual acuity of the left eye in the patient was lost three days earlier than that of the right eye; as a result of treatment, the BCVA in the left eye was lower than that in the right eye. The results of this study demonstrate that we should pay attention to intracranial changes as soon as possible in patients with a sharp decline in visual acuity but with no obviously positive signs in the eyeball.

Funding

This study was supported by the Innovation Cultivating Foundation of 6th Medical Centre of People's Liberation Army General Hospital (no. CXPY2017020).

References

1. Hahn LD, Fulbright R, Baehring JM. Hypertrophic pachymeningitis. J Neurol Sci. 2016;367:278-83.
2. Cacao G, Calejo M, Alves JE, Medeiros PB, Vila-Cha N, Mendonca T, et al. Clinical features of hypertrophic pachymeningitis in a center survey. Neurol Sci. 2019;40(3):543-51.
3. Roongpiboonsopit D, Phanthumchinda K. Idiopathic hypertrophic pachymeningitis at King Chulalongkorn Memorial Hospital. J Med Assoc Thai. 2014;97(4):374-80.
4. Mathew RG, Hogarth KM, Coombes A. Idiopathic hypertrophic cranial pachymeningitis presenting as acute painless visual loss. Int Ophthalmol. 2012;32(2):195-7.
5. Kupersmith MJ, Martin V, Heller G, Shah A, Mitnick HJ. Idiopathic hypertrophic pachymeningitis. Neurology. 2004;62(5):686-94.
6. Dash GK, Thomas B, Nair M, Radhakrishnan A. Clinico-radiological spectrum and outcome in idiopathic hypertrophic pachymeningitis. J Neurol Sci. 2015;350(1-2):51-60.
7. Jacobi D, Maillot F, Hommet C, Arsene S, Cottier JP, Lamisse F, et al. P-ANCA cranial pachymeningitis: A case report. Clin Rheumatol. 2005;24(2):174-7.
8. Tsugawa J, Ouma S, Fukae J, Tsuboi Y, Sakata N, Inoue T. Multiple cranial neuropathies in a patient with IgG4-related hypertrophic pachymeningitis: A case report. Brain Nerve. 2014;66(7):873-8.