



## Maternal Blood Aspiration Syndrome

Zozaya C\*, Magariño P, Villar G, Cuesta MT, Castro A and Cabanillas L

Neonatology Section, Getafe University Hospital, Madrid, Spain

### Abstract

Respiratory distress in newborns within the first hours after birth includes airway obstruction etiologies. Among them, the leading cause is meconium aspiration. However, other substances can stain amniotic fluid as well and share common pathogenic mechanisms. Maternal blood aspiration is a specific diagnostic entity and should be considered in any newborn baby with respiratory distress or apnea of unknown cause. We present a case of blood aspiration syndrome along with melena neonatorum with Apt test maternal hemoglobin confirmation.

**Keywords:** Respiratory distress; Amniotic fluid; Placental inspection

### Introduction

Respiratory distress in the newborn baby within the first hours after birth includes airway obstruction due to diverse substances. Among them, meconium aspiration has centered most of the literature attention. However, other substances can stain amniotic fluid as well and share common pathogenic mechanisms. Maternal blood aspiration is a specific diagnostic entity, probably underdiagnosed. It should be considered in any newborn baby with respiratory distress or apnea of unknown cause.

### Case Presentation

A female newborn baby was born by spontaneous vaginal delivery at 36+4 weeks of gestational age. Birth weight: 2,695 g. Amniotic fluid was hemorrhagic. There was no data to suggest fetal distress. Placental inspection revealed no anomalies at insertion.

The patient showed inefficient respiratory effort at birth and bradycardia which did not improve after upper airway secretions suction (red blood) and intermittent positive pressure ventilation (1 min). Endotracheal intubation was required at 1½ minutes from birth. Apgar test scores were 5 at 1 min and 6 at five min of life. Umbilical artery pH was 7.32 and base excess was 8.9. From the first minute of life, copious and continuous bloody stool passage was noted (Figure 1). Antihemorrhagic prophylaxis was administered in the delivery room.

The patient required conventional mechanical ventilation (maximum FiO<sub>2</sub> 0.4) for 14 h and CPAP for 6 h after extubation. Chest X-ray (Figure 2) showed parenchymal opacification with bilateral infiltrates and increased lung volume (8-9 intercostal spaces). Tracheal suction was often needed during the first hours and revealed fresh red blood. Laboratory results showed hemoglobin 15.1 g/dL and platelet count and coagulation parameters were within the normal range. The patient did not have hemodynamic instability signs at any time. A rectal blood sample was sent to Apt-Downey test performance which confirmed adult hemoglobin origin.

Enteral feedings were started at 44 h with breast milk with suboptimal tolerance at beginning. Bloody stools and gastric residual lasted until the fourth day. Ranitidine treatment was implemented. Full enteral nutrition was achieved at 4<sup>th</sup> day. The patient was discharged after 5 days and evaluated at 9 days old in the outpatient clinic where no sequels were found.

### Discussion

Respiratory distress at birth can be secondary to amniotic fluid aspiration stained with meconium [1], vernix [2], cellular debris [3,4] maternal blood [5] or even clear amniotic liquid [6]. Immediate respiratory distress along with hemorrhagic amniotic fluid and blood in upper and lower airway aspirates and melena raised the clinical suspicion for blood aspiration syndrome. Blood aspiration syndrome affects predominantly term or late preterm neonates and surprisingly all reported cases were female.

A patent maternal bleeding is not always found and amniotic fluid might be clear which has

### OPEN ACCESS

#### \*Correspondence:

Zozaya C, Neonatology Section, Getafe University Hospital, Madrid, Spain,  
E-mail: zozai6@hotmail.com

Received Date: 01 Aug 2017

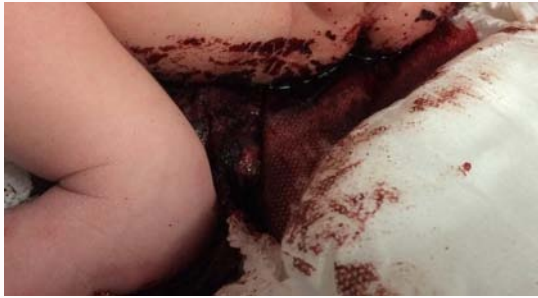Accepted Date: 25 Aug 2017

Published Date: 31 Aug 2017

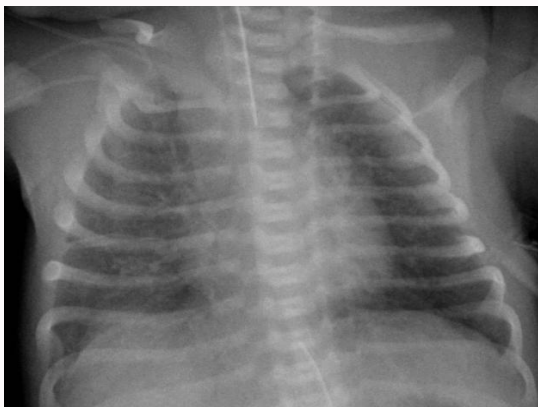
#### Citation:

Zozaya C, Magariño P, Villar G, Cuesta MT, Castro A, Cabanillas L. Maternal Blood Aspiration Syndrome. *Clin Case Rep Int.* 2017; 1: 1018.

**Copyright** © 2017 Zozaya C. This is an open access article distributed under the Creative Commons Attribution License, which permits unrestricted use, distribution, and reproduction in any medium, provided the original work is properly cited.



**Figure 1:** Bloody stool passage from first minute.



**Figure 2:** Increase in lung volume.

been noticed at least in two previous reported cases [7]. However, it has been postulated, based in post mortem studies [5], that a small volume of blood can be enough to completely fill a newborn's lung space. When a neonate's head is engaged in the birth canal, the mouth is directly exposed to the uterine wall and its contractions could potentially induce aspiration of blood products. In other cases, maternal hemorrhage was obvious and amniotic fluid was bloody, as it was in our case. It has been reported bloody upper airway secretions at birth in up to 43% of deliveries by cesarean section [8]. Abruptio placentae indeed can be another specific risk factor for this condition.

Chest X-ray is usually consistent with an aspiration syndrome. Hyperinflation with varying degrees of lung opacification has been described as its main features. Apt-Downey [9,10] or Kleihauer-Betke tests might be used to determine the maternal origin of the blood. In other cases, diagnosis has been determined by high plasmatic concentrations in lung fluid [7].

Differential diagnosis should consider lung hemorrhage, which usually manifests as severe respiratory distress, massive bleeding, thrombopenia and coagulopathy [11]. Apt test determined maternal origin in our patient.

Supportive care remains as the treatment of choice. All previously published cases required mechanical ventilation. The true incidence of maternal blood aspiration syndrome at birth remains unknown and it most likely is an underdiagnosed entity, especially in mild cases. In fact, all reported patients required conventional mechanical ventilation but around half of them were initially

managed in a conservative manner (age at endotracheal intubation ranges from birth to 5 h). In the alveolar barrier, blood products inactivates surfactant function and harm type II pneumocytes. This could explain the progressive worsening course and relatively good condition at birth described in some patients. Exogenous surfactant replacement treatment has been considered as a potential treatment in lung hemorrhage cases [12] and it has successfully been used in blood aspiration syndrome as well [13].

Prognosis appears to be favorable and ventilator support is often withdrawn within the first 72 h and systemic complications are rare although secondary hemoglobinuria [14] multiorgan failure [15] and death [5] have been reported following maternal blood aspiration.

## References

1. Lindenskov PH, Castellheim A, Saugstad OD, Mollnes TE. Meconium aspiration syndrome: Possible pathophysiological mechanisms and future potential therapies. *Neonatology*. 2015;107(3):225-30.
2. Nishijima K, Shukunami KI, Inoue S, Kotsuji F. Management for neonatal aspiration syndrome caused by vernix caseosa. *Fetal Diagn Ther*. 2005;20(3):194-6.
3. Perlman M, Bar-Ziv J. Congenital ichthyosis and neonatal pulmonary disease. *Pediatrics*. 1974;53(4):573-5.
4. Reyat F, Sinicot M, Danan C, Gerard M, Haddad B. Disseminated bronchoalveolar keratinocyte plugs in severe neonatal congenital lamellar ichthyosis. *Fetal Diagn Ther*. 2015;20(1):10-1.
5. Ceballos R. Aspiration of maternal blood in the etiology of massive pulmonary hemorrhage in the newborn infant. *J Pediatr Elsevier*. 1968;72(3):390-3.
6. de Cunto A, Paviotti G, Demarini S. Neonatal aspiration: not just meconium. *J Neonatal Perinatal Med*. 2013;16(4):355-7.
7. Gordon E, South M, McDougall PN, Dargaville PA. Blood aspiration syndrome as a cause of respiratory distress in the newborn infant. *J Pediatr*. 2003;142(2):200-2.
8. Pender CB. Respiratory distress in the newborn infant due to blood aspiration in infants delivered by cesarean section. *Am J Obstet Gynecol*. Elsevier. 1970;106(5):711-7.
9. Apt L, Downey WS. Melena neonatorum: the swallowed blood syndrome; a simple test for the differentiation of adult and fetal hemoglobin in bloody stools. *J Pediatr*. 1955;47(1):6-12.
10. Crook M. Haemoglobin in stools from neonates: measurement by a modified Apt-test. *Med Lab Sci*. 1991;48(4):346-7.
11. Deodhar J, Kadam S, Pharande P, Vaidya U, Pandit A. Maternal blood aspiration: an unusual cause of respiratory distress in a neonate. *Ann trop paediatr*. 2006;26(3):255-7.
12. Aziz A, Ohlsson A. Surfactant for pulmonary haemorrhage in neonates. *Cochrane Database Syst Rev*. 2012;2012(7):Cd005254.
13. Celik IH, Demirel G, Canpolat FE, Erdeve O, Dilmen U. Surfactant therapy for maternal blood aspiration: An unusual cause of neonatal respiratory distress syndrome. *Indian J Pediatr*. 2012;79(10):1358-9.
14. Saia OS, Gasparotto G. Macroscopic hemoglobinuria in a neonate with massive blood aspiration. *J Pediatr*. 1982;101(3):446-7.
15. Patrick S, Kershaw D, Attar M. Multiple organ dysfunctions following aspiration of maternal blood. *Internet J Pediatr Neonatol*. 2012;14(1):14224.