



## Dish: An Uncommon Cause of Dysphagia in the Elderly

Leonello Tacconi\*, Simone Ulivieri and Francesco Iacoangeli

Department of Neurosurgery, University Hospital of Siena, Italy

### Abstract

Diffuse Idiopathic Skeletal Hyperostosis, also known as DISH or Forestier-Rotes-Querol disease can be an uncommon cause of Dysphagia. The prevalence of DISH can vary between 2.9% and 28%. It is a pathology consisting in an abnormal ossification of the spine that brings to a hyperostosis of the anterior column particularly in the cervical and thoracic tracts which can cause symptoms due to the compression of the surrounding tissues. Very often this entity is asymptomatic but when the calcification becomes abundant it can cause symptoms like dysphagia, dysphonia, and dyspnea. This entity must be kept into differential diagnosis with other pathologies which may affect patients over 60 years old. In this article we report the case of a 75 year old gentleman affected by DISH, which was successfully operated with completely resolution of the symptoms.

**Keywords:** DISH; Dysphonia; Ossification; Spine; Cervical region

### Introduction

Dysphagia may be a common symptom in the elderly and can be due to an anatomical narrowing or a dysfunction of the neuronal plexus embedded in the esophagus wall. The reduction of the lumen caliber may be due to different causes like intrinsic tumors, post Esophagitis fibrosis or extrinsic compression from masses of the surrounding tissue, like vascular, bony or soft tissue structures [1]. This pathological entity was described for the first time in 1950 and named Forestier and Rotes-Querol Syndrome. It has a variable prevalence ranging from 2.9% to 28% [2]. Recently, it has been called Diffuse Idiopathic Skeletal Hyperostosis (DISH) being a different condition from Ankylosis Spondylosis. It is a non-inflammatory condition, which usually affects elderly man and is mainly characterized by calcification and ossification of the anterior longitudinal ligaments with osteophytes formation especially in the thoracic and lumbar region. The causes of this condition are unknown but risks factors have been identified in obesity, male gender, and diabetes and advance age. Patients with spinal DISH can also complain for local pain during active or passive movements, stiffness and dysphonia. This last symptom is due to vocal cords irritation from food false ways intakes or recurrent laryngeal nerve irritation from osteophytes compression. The majority of these cases are found incidentally on imaging and patients are generally asymptomatic [3]. When they become symptomatic can present with a mild dysphagia to difficult food intake and sometimes, even, airway compromise [4]. The condition may be treated conservatively in most patients, although in some cases surgical intervention can become compulsory because of the severity of the symptoms and yield very good clinical results.

### Case Report

A 77-year-old chronic smoker male presented with 12-months history of cough and sore throat which progressively ended in severe dysphagia and weight loss. He underwent chest x-rays to rule out a bronchial or pulmonary cause for his cough, which resulted negative. A dynamic barium swallow x-ray study revealed abnormal pharyngeal dynamics, with altered epiglottis tilt, and esophagus lumen narrowing. A cervical CT spine scan revealed a huge anterior cervical osteophyte extending from C3 to C6 with a maximum width of 27 mm. A MRI confirmed the esophagus extrinsic compression by the big osteophyte. Because of the severity of the dysphagia a surgical treatment, at that stage, had become necessary. He underwent an anterior cervical surgical approach (Figure 1) and the Osteophylectomy performed by drilling off all the abnormal bone growth (Figure 2). After surgery the patient was fed, for a few days by a naso-gastric tube and two weeks later he could start eating by mouth and was back to a normal food intake within a month. The histology showed to be bony formation with some elements of fibrous and cartilaginous tissue. At a six month follow up the patient was fine with no neurological symptoms and had regained his normal body mass index.

### OPEN ACCESS

#### \*Correspondence:

Leonello Tacconi, Department of Neurosurgery, University Hospital of Siena, River Road 447, Trieste, 34100, Italy, Tel: 390403994144; Fax: 390403994735; E-mail: [leonello.tacconi@asuils.sanita.fvg.it](mailto:leonello.tacconi@asuils.sanita.fvg.it)

Received Date: 02 May 2018

Accepted Date: 06 Jun 2018

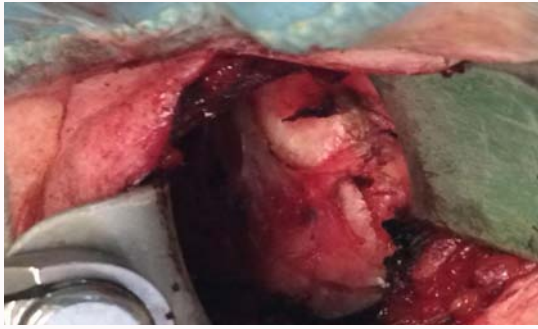Published Date: 14 Jun 2018

#### Citation:

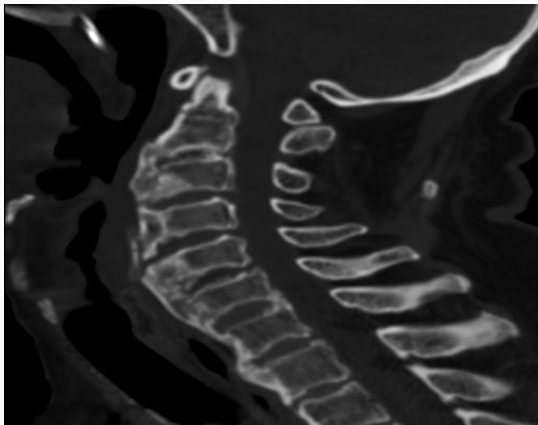
Tacconi L, Ulivieri S, Iacoangeli F. Dish: An Uncommon Cause of Dysphagia in the Elderly. *Clin Case Rep Int.* 2018; 2: 1055.

Copyright © 2018 Leonello Tacconi.

This is an open access article distributed under the Creative Commons Attribution License, which permits unrestricted use, distribution, and reproduction in any medium, provided the original work is properly cited.



**Figure 1:** Sagittal CT scan showing cervical anterior osteophytes from C3 to C6.



**Figure 2:** Intraoperative view showing the anterior cervical bony and cartilaginous anterior extensive osteophyte.

## Discussion

From a biomechanical point of view the great load-bearing and mobility properties of C5 and C6 segment of the cervical spine makes it the most common site of cervical disk and bone degeneration with consequent osteophytes development [5]. The anatomical position of the esophagus which lies just among the anterior aspect of the cervical spine from C4 to C7 and its soft wall consistency makes this organs very vulnerable to any external mechanical compression. These can lead to a lumen narrowing and local tissue inflammation resulting in cricopharyngeal spasms and esophageal wall denervations. Epiglottis tilt can also be impaired and ab-ingestis episodes can happen [6]. Although more than 75% of people aged 65 and older suffer from various degrees of spine degenerative changes and the prevalence of anterior cervical osteophytes is around 3% to 30% in the elderly population [4], DISH remains a rare cause of dysphagia. Even if very rarely, DISH can also affect the lumbar region [1]; or be associated with ossification of the stylohyoid ligament (Eagle syndrome) [5]. Resnick proposed the presence of diagnostic features to make the diagnosis of DISH (Reskin Criteria) including: 1) ossification of the anterior longitudinal ligament; 2) osteophytes developing among at least four cervical vertebral bodies; 3) absence of important degenerative disc pathology and 4) no apophyseal joint ankylosis or sacroiliac joint sclerosis [5]. As matter of fact large cervical osteophytes can occur as well as in severe cervical spondylosis and ankylosing spondylitis [6]. Generally this condition may be, at the beginning, asymptomatic

or presents itself with some mild recurrent episodes of dysphagia [7]. Also episodes of coughing may happen like in the case we have reported and may precede by months more important episodes of swallowing problems. Initially it can be more a mechanical type impairment towards solid food which can evolve, over a period of months to years, also for liquid (orthodox dysphagia). The diagnosis may be very simple with the standard radiological investigations. A plain x-ray may show the presence of a calcified mass localized anteriorly to the vertebral body. This finding can be better seen on a CT scan especially if performed with 3D reconstruction. An MRI can delineate the relationship among the esophagus, the compressing factor and the surrounding structures [8]. A fiber-optic endoscopic evaluation of swallowing may show residues of food in the pharynx and a barium swallow x-ray may detect some abnormality in the swallowing process or esophagus narrowing. The management of DISH is typically multidisciplinary and treatment is primarily medical after having excluded other causes of dysphagia like the presence of a tumor. The first line of conservative treatment consists in a dietary modifications (semisolid diet), swallowing rehabilitation and NSAIDs [9]. However, when conservative treatment has failed or we are in the presence of giant osteophytes, surgery must be considered [10]. The surgical timing is a crucial point because if we reach a stage where degenerative changes have happened within the esophagus wall with disruption and fibrosis of the nervous plexus and surrounding tissue a functional recovery, also after a successful operation, may be irreversible.

## References

- Seidler TO, Pérez Alvarez JC, Wonneberger K, Hacki T. Dysphagia caused by ventral osteophytes of the cervical spine: Clinical and radiographic Findings. *Eur Arch Otorhinolaryngol*. 2009;266(2):285-91.
- Kim SK, Choi BR, Kim CG, Chung SH, Choe JY, Joo KB, et al. The prevalence of diffuse idiopathic skeletal hyperostosis in Korea. *J Rheumatol*. 2004;31(10):2032-5.
- Lecerf P, Malard O. How to diagnose and treat symptomatic anterior cervical osteophytes? *Eur Ann Otorhinolaryngol Head Neck Dis*. 2010;127(3):111-6.
- Alexander CE, Eric SK, Darrin JL, Jonathan JL, Gilbert C, Ripul RP, et al. Dysphagia secondary to anterior osteophytes of the cervical spine. *Global Spine J*. 2015;5(5):e78-83.
- Calisaneler T, Ozdemir O, Tosun E, Altinors N. Dysphagia due to diffuse idiopathic skeletal hyperostosis. *Acta Neurochirurgica*. 2005;147(11):1203-6.
- Forestier J, Rotes-Querol J. Senile ankylosing hyperostosis of the spine. *Ann Rheum Dis*. 1950;9(4):321-30.
- Sebaaly A, Boubez G, Sunna T, Wang Z, Alam E, Christopoulos A, et al. Diffuse idiopathic hyperostosis manifesting as dysphagia and bilateral cord paralysis: A case report and literature review. *World Neurosurg*. 2018;111:79-85.
- Chen Y, Sung K, Tharin S. Symptomatic anterior cervical osteophyte causing dysphagia: Case report, imaging and review of the literature. *Cureus*. 2016;8(2):e473.
- Curtis JR, Lander PH, Moreland LW. Swallowing difficulties from "DISH-phagia". *J Rheumatol*. 2004;31(12):2526-7.
- Sirshak D, Kaustuv DB, Ankur M, Asimjiban B, Saumik D, Indranil S. Dysphagia due to forestier disease: Three cases and systematic literature review, Indian. *J Otolaryngol Head Neck Surg*. 2014;66(1):379-84.