



## A Stomach in the Stomach: A Huge Trichobezoars in Young Female

Ehab F Moustafa<sup>1\*</sup>, Sahar M Hassany<sup>1</sup> and Bashir A Fadel<sup>2</sup>

<sup>1</sup>Tropical Medicine and Gastroenterology Department, Al-Rajhy liver and Gastroenterology Hospital, Assiut University, Egypt

<sup>2</sup>Hepato-biliary Surgery Department, Al-Rajhy liver and Gastroenterology Hospital, Assiut University, Egypt

### Case Blog

An 18-year-old female patient presented by vomiting of 2 years duration related to meals, progressive course and associated with loss of weight. On examination she was pale and under build. Abdominal examination revealed epigastric mass 13 cm × 8 cm, soft in consistency with ill define border. Abdominal ultrasound showed dilated stomach with contents inside. Abdominal CT suggested gastric Trichobezoars (Figure 1). Upper Endoscopy revealed huge gastric trichobezoars start just below cardia with multiple min ulcers. Laparotomy was done and stomach like trichobezoars removed (Figure 2). After recovery patient stopped vomiting and start body gain. Patient refused psychiatric consultation.

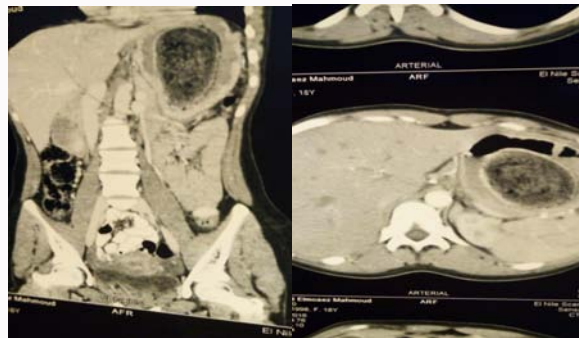


Figure 1: Abdominal CT suggested gastric Trichobezoars.

### OPEN ACCESS

#### \*Correspondence:

Ehab F Moustafa, Tropical Medicine and Gastroenterology Department, Al-Rajhy liver and Gastroenterology Hospital, Assiut University, Egypt, E-mail: ehab\_mostafa99@yahoo.com

Received Date: 24 Jun 2017

Accepted Date: 27 Sep 2017

Published Date: 04 Oct 2017

#### Citation:

Moustafa EF, Hassany SM, Fadel BA. A Stomach in the Stomach: A Huge Trichobezoars in Young Female. Clin Case Rep Int. 2017; 1: 1025.

Copyright © 2017 Ehab F Moustafa.

This is an open access article distributed under the Creative Commons Attribution License, which permits unrestricted use, distribution, and reproduction in any medium, provided the original work is properly cited.

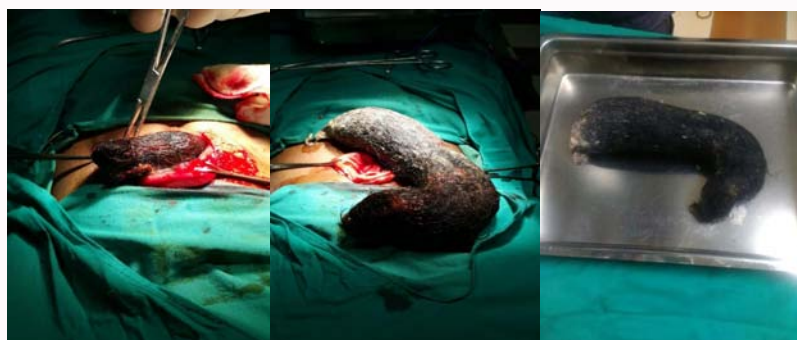

Figure 2: After laprotomy, removal of stomach like trichobezoars.