



## An Unusual Culprit of a Rectal Bleed

Nicholas Armstrong C<sup>1\*</sup>, Sharjeel Pau<sup>2</sup> and Joseph Garvin<sup>2</sup>

<sup>1</sup>University of Limerick, Graduate Entry Medical School, Ireland

<sup>2</sup>Portiuncla University Hospital, Galway, Ireland

### Abstract

**Presentation:** An 83-year-old man presented to hospital with 3 to 4 episodes of rectal bleeding consisting of dark red blood with clots.

**Diagnosis:** Routine management for per rectal bleeding commenced including blood work, radiological imaging and endoscopy. This patient's condition presented a diagnostic challenge in determining the origin and culprit of this rectal bleed.

**Treatment:** The patient's bleed was managed and treated *via* therapeutic endoscopy. This patient then underwent palliative care shortly after and passed away due to progression of his metastatic disease.

**Conclusion:** The identification and management of metastatic prostate cancer with colorectal involvement is rare and requires a more robust literature to improve the management of these patients. Obtaining the correct diagnosis is critical since there are differences in the treatment and prognosis of metastatic prostatic cancer with colonic involvement compared to primary rectal carcinoma.

### Introduction

Prostatic cancer is a relatively common malignancy with about 1 in 9 men receiving this diagnosis in their lifetime. The major prognostic factor is the presence of metastases [1]. Prostate cancer has the potential to advance loco-regionally to adjacent organs by direct invasion *via* Denonvilliers fascia to the rectum, lymphatic channels, and hematogenously (Batson's venous plexus) [2]. Advanced prostate cancer can cause pelvic symptoms that can significantly impair the patient's quality of life. This can include the common urinary symptomatology and more rarely obstructive rectal symptoms and per rectal bleeding. The incidence of rectal infiltration by prostatic adenocarcinoma is extremely rare, being encountered on average once every two years by a busy colorectal practice [3].

### OPEN ACCESS

#### \*Correspondence:

Nicholas Armstrong C, University of Limerick, Graduate Entry Medical School, Ireland, Tel: 353-083-874-0950; E-mail: Nicholas.armstrong@mail.utoronto.ca

Received Date: 02 Mar 2021

Accepted Date: 22 Mar 2021

Published Date: 25 Mar 2021

#### Citation:

Nicholas Armstrong C, Paul S, Garvin J. An Unusual Culprit of a Rectal Bleed. Clin Case Rep Int. 2021; 5: 1221.

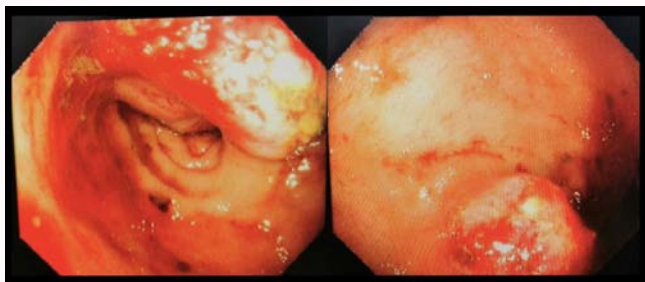
**Copyright** © 2021 Nicholas Armstrong C. This is an open access article distributed under the Creative Commons Attribution License, which permits unrestricted use, distribution, and reproduction in any medium, provided the original work is properly cited.

### Case Presentation

This case report is of an 83-year-old male who presented to hospital with a five-day history of per-rectal bleeding on a background history of prostate cancer with diffuse bony metastases. This was the first presentation with per rectal bleeding. The patient reported 3 to 4 episodes of dark red blood mixed with clots described as approximately 15 mL each. Hematological blood tests revealed the patient had low levels of hemoglobin (6.0 d/dL) and platelets ( $57 \times 10^9/L$ ). The patient also had an elevated alkaline phosphatase (2367 IU/L) which is to be expected in a patient with metastatic prostate cancer.

Radiological assessment of the patient included a contrast CT scan of the abdomen and pelvis which showed extensive blastic metastases with calcification and enlargement of the prostate gland. The most significant and unusual finding was a large irregular prostatic mass noted to be extending posteriorly involving the rectum and contained multiple calcifications. Radiological impression was that this metastatic mass in the rectum may have been the culprit of this patient's PR bleed. Following this the patient underwent a CT angiogram which revealed a blush on the anterior wall of the rectum, which was indicative of irregular or primitive vasculature.

The patient then underwent colonoscopy to determine the origin of the bleed and was treated with Argon Plasma Coagulation (APC) and Hemocler<sup>TM</sup>. The bleeding was localized to one region and was not circumferential, as is commonly seen in radiation induced proctitis. Once the bleed was controlled the patient was managed by surgical and palliative care teams. X-rays taken during the patient's hospital stay revealed worsening of the metastatic disease and as a result of this the patient



**Figure 1:** Colonoscopic images of the invasive prostatic adenocarcinoma with rectal involvement in this patient.

passed weeks later [4,5] (Figure 1).

## Discussion

There is a lack of robust literature on the topic of metastatic prostate cancer with colon involvement. The majority of general surgeons manage complications of prostatic adenocarcinoma treatment regimens, including radiation induced proctitis. In radiotherapy for prostate cancer, the rectum is the major dose-limiting structure [6]. It is unclear from this patient's history whether a prostate-rectum spacer was utilized to reduce rectal toxicity during his radiotherapy treatment.

To identify the culprit of a rectal bleed when suspecting prostate CA invasion serum Prostate Specific Antigen (PSA) and immunohistochemical staining of rectal biopsy specimens are useful diagnostic tools [7]. To confirm the diagnosis biopsied tissue should be stained with an immunohistochemical panel consisting of PSA, Prostatic Acid Phosphate (PAP), Cytokeratin-20 (CK20) and Carcinoembryonic Antigen (CEA) [8,9].

In summary we discuss an 83-year-old male with an unusual cause of rectal bleeding on a background history of metastatic prostate carcinoma. The patient presented to the emergency department with a 5-day history of per rectal bleeding, and was treated but died weeks later as a result of worsening metastatic disease. There is a

lack of robust literature on the identification and management of this condition. Obtaining the correct diagnosis is critical for future patients as treatment and prognosis for metastatic prostate cancer with rectal involvement differs from primary carcinoma of the rectum. Immunohistological analysis of tissue biopsy is considered the gold standard in determining the culprit of the unusual causes of rectal bleeds.

## References

1. Gundem G, Van Loo P, Kemmerer B, Alexandrov LB, Tubio JM, Papaemmanuil E, et al. The evolutionary history of lethal metastatic prostate cancer. *Nature*. 2015;520(7547):353-7.
2. Abbas TO, Al-Naimi AR, Yakoob RA, Al-Bozom IA, Alobaidly AM. Prostate cancer metastases to the rectum: A case report. *World J Surg Oncol*. 2011;9(56):1-3.
3. Bowrey DJ, Otter MI, Billings PJ. Rectal infiltration by prostatic adenocarcinoma: Report on six patients and review of the literature. *Ann R Coll Surg Engl*. 2003;85(6):382-5.
4. Fry DE, Amin M, Harbrecht PJ. Rectal obstruction secondary to carcinoma of the prostate. *Ann surg*. 1979;189(4):488-92.
5. Susil RC, McNutt TR, DeWeese TL, Song D. Effects of prostate-rectum separation on rectal dose from external beam radiotherapy. *Int J Radiat Oncol Biol Phys*. 2010;76(4):1251-8.
6. Melegh Z, Oltean S. Targeting angiogenesis in prostate cancer. *Int J Mol Sci*. 2019;20(11):2676.
7. Winter C. The problem of rectal involvement by prostatic cancer. *Surg Gynecol Obstet*. 1957;105(2):136-40.
8. Murray SK, Breau RH, Guha AK, Gupta R. Spread of prostate carcinoma to the perirectal lymph node basin: Analysis of 112 rectal resections over a 10-year span for primary rectal adenocarcinoma. *Am J Surg Pathol*. 2004;28(9):1154-62.
9. Gengler L, Baer J, Finby N. Rectal and sigmoid involvement secondary to carcinoma of the prostate. *Am J Roentgenol Radium Ther Nucl Med*. 1957;125(4):910-7.