



## Assessing the Role of WT1 in Young Sudden Cardiac Death: The Value of Immunohistochemical Diagnostics

Cămărășan A<sup>1</sup>, Cămărășan O<sup>2</sup>, Buhaș C<sup>1</sup>, Vilceanu N<sup>1</sup>, Vilceanu I<sup>1</sup>, Pașcalau A<sup>1</sup>, Pop-Crișan A<sup>3</sup> and Pop O<sup>1\*</sup>

<sup>1</sup>Department of Morphological Disciplines, University of Oradea, Bihor County, Romania

<sup>2</sup>Prof. Dr. Ioan Pușcaș Hospital Șimleu Silvaniei, Sălaj County, Romania

<sup>3</sup>Department of Surgical Disciplines, University of Oradea, Bihor County, Romania

### Abstract

The first responsible for the occurrence of sudden cardiac death in young adults are primary cardiomyopathies and channelopathies. Wilms' Tumor Protein (WT1) is a suppressor gene meet in embryological cardiac development which seems to reactivate during cardiac injuries.

Forty (40) cases were included in the study from Forensic Department belong to the Bihor County. Fragments of heart tissue were collected from sudden cardiac deaths in people aged 18 to 40 years. Those sections of the heart were chosen with macroscopic obvious pathological changes, but also sections of the heart without any type of macroscopic changes. Twenty-four cases had correlations established between the macroscopic and microscopic aspects of acute myocardial infarction.

However, in 16 cases the diagnosis of death because of acute myocardial infarction could not be established by identifying macroscopic lesions. In such cases it is important to use the WT1 immunomarker to confirm the diagnosis of ischemic cardiovascular disease. The H score performed, ranged between 30 and 280, showed overexpression of WT1 gene in both groups, the group with macro-/microscopic cardiac lesions and the group without any macro-/microscopic cardiac lesions. All 10 cases included in the control group did not show overexpression of the WT1 gene (score H=0). The analysis of standard errors reveals a homogeneity of the lots included in the study. This fact ensures a statistical relevance of the results obtained.

The use of immunohistochemical techniques to highlight the expression of WT1 can help in the definite diagnosis of acute myocardial infarction in the case of deaths shortly after the onset of the disease. In the case of patients belonging to the forensic department, WT1 plays an important role in establishing with certainty the cause of death.

**Keywords:** Immunohistochemistry; WT1; Acute myocardial infarction; Sudden Cardiac Death

### Introduction

Most sudden deaths are caused by cardiovascular pathologies, the term used for this type of death being sudden cardiac death [1]. Sudden cardiac death is the sudden, unexpected death of a cardiac cause installed at a person in apparent full health, without symptoms, or with symptoms that started a maximum of 1 h before death [1,2]. The main cause of sudden cardiac death is atherosclerotic coronary pathology, which mainly affects adults in the second and third years of life [3]. In young adults, sudden death is one of the major causes of death [4], primary cardiomyopathies (hypertrophic, idiopathic left ventricular hypertrophy) and channelopathies are the first responsible for the occurrence of sudden cardiac death, and congenital coronary anomalies are in second place [3]. Other causes of sudden cardiac death in young people, rarer, are: Mitral valve prolapse, myocarditis, sarcoidosis, pulmonary hypertension, myocardial hypertrophy, pulmonary embolism, hemodynamic and systemic metabolic alterations, administration of toxic substances such as cocaine and methamphetamines [5,6].

Wilms' Tumor Protein (WT1) is a suppressor gene located on Chromosome 11p13. During the phylogenetic development, stem cells are found at the level of the epicardium. Cardiac injuries can induce the reactivation of this embryological mechanism of activation of the resident cardiac progenitor cells. The WT1 gene is associated expressed during the period of epicardial activation.

The small number of studies related to the expression of WT1 in relation to cardiac regeneration

### OPEN ACCESS

#### \*Correspondence:

Ovidiu Pop, Department of Morphological Disciplines, University of Oradea, Bihor County, Romania, E-mail: drovipop@yahoo.com

Received Date: 17 Feb 2023

Accepted Date: 02 Mar 2023

Published Date: 06 Mar 2023

#### Citation:

Cămărășan A, Cămărășan O, Buhaș C, Vilceanu N, Vilceanu I, Pașcalau A, et al. Assessing the Role of WT1 in Young Sudden Cardiac Death: The Value of Immunohistochemical Diagnostics. *Clin Case Rep Int.* 2023; 7: 1505.

**Copyright** © 2023 Pop O. This is an open access article distributed under the Creative Commons Attribution License, which permits unrestricted use, distribution, and reproduction in any medium, provided the original work is properly cited.

limits the relevant information related to the mechanisms of cardiac regeneration. Myocardial endothelial cells reveal the diffuse presence of WT1 in regenerating cells compared to the reduced expression of the WT1 gene in the case of the adult heart.

Recent studies show a temporal overexpression of the WT1 gene in the endothelial cells of the infarcted area and at the border area of the heart. Certain scientific hypotheses reveal an association between the absence of WT1 expression in endothelial cells and vascular regeneration post-myocardial infarction [7].

## Material and Method

The study carried out is analytical, prospective, observational type and included 40 cases. The selected cases came from the Bihor County Forensic Service, collected in a time interval between January 01<sup>st</sup>, 2018 and June 15<sup>th</sup>, 2022. In order to fulfill the tasks in the study, human heart fragments were collected from deceased persons within the Bihor County that are the subject of legal medicine. The control group consisted of 10 consecutive newborns who died in the same period, without any cardiac or malignant diseases.

Fragments of heart tissue were collected from sudden cardiac deaths in people aged 18 to 40 years. Those sections of the heart were chosen with macroscopic obvious pathological changes, but also sections of the heart without any type of macroscopic changes. The tissue fragments were fixed in buffered formalin for a period of 48 h to 72 h. Tissue processing was performed automatically with the Excelsior platform, according to the manufacturer's insert (Eprexia-Portsmouth, New Hampshire-USA). The paraffin-embedded tissue was sectioned using the Leica RM2125 microtome (Leica Biosystem, Buffalo Grove, IL, US) at 4 microns, being stained standardized with the Gemini automatic Stainer (Eprexia-Portsmouth, New Hampshire-USA).

Paraffin-embedded fixed cardiac tissues, 4 μm thick sections, were stained by Ventana Benchmark GX (Ventana Medical Systems Inc., Tucson, AZ, USA). Following the manufacturer's instructions, the slides were deparaffinized using EZ prep solution (Ventana Medical Systems, Inc.), incubated with monoclonal antibodies, developed using the Opti View DAB detection kit (Ventana Medical Systems, Inc.), and counterstained with hematoxylin and bluing. For WT1 reactivity, sections were incubated with WT1 primary monoclonal antibody (EPR1653, rabbit, IgG, membranous/cytoplasmatic, IVD-Ventana Medical Systems Inc., Tucson, AZ, USA) in accordance with the manufacturer's protocol [8,9].

For each run, a positive control slide was performed.

The specimens were analyzed by two skilled pathologists and were double blinded according with H score. The H score is determined by multiplying the percentage of cells demonstrating each intensity (scored from 0 to 3) and adding the results. There are 300 possible values. In this system, <1% positive cells are considered to be a negative result [10].

The image acquisition was performed using a microscope with intelligent automation, Leica DM3000 LED and LAS EZ Software (provided by Leica Biosystem, Buffalo Grove, IL, USA).

The numerical variables were analyzed using GraphPad Prism 8.0 Software program. Standard deviation, mean values were represented in statistical graph charts.

## Results

From the total of 40 patients included in the study, only in a number of 24 cases had correlations established between the macroscopic and microscopic aspects of acute myocardial infarction. However, an important number of cases remains (16 out 40 cases) in which the diagnosis of death, acute myocardial infarction, could not be made by identifying macroscopic lesions. In these cases, there were discrepancies between the patient's clinical history and the cause of death (Table 1). In such cases it is important to use the WT1 immunomarker to confirm the diagnosis of ischemic cardiovascular disease.

In our study WT1 immunohistochemical marking was performed in all 40 cardiac samples. The microscopic evaluation was made by Hematoxylin Eosin (data not shown).

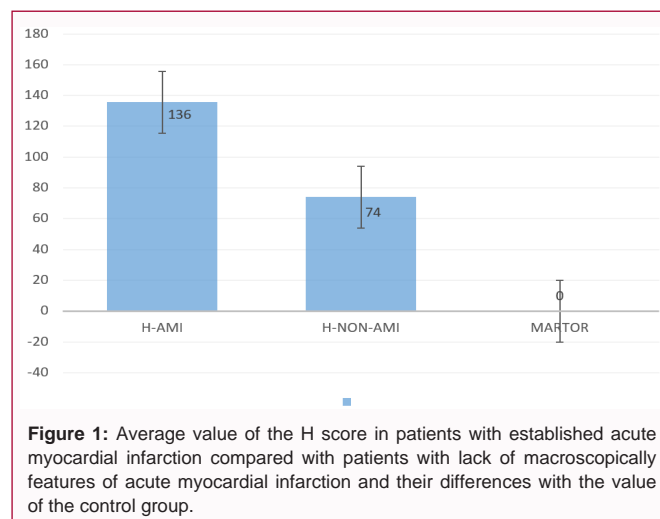
The overexpression of the WT1 gene evaluated by achieving the H score revealed values between minimum 30 and maximum 280. It should be mentioned that in all cases the overexpression of the WT1 gene was identified (100%).

The analysis of the cases that presented a presumptive diagnosis of acute myocardial infarction but without obvious macroscopic lesions, revealed the fact that the expression of WT1 is lower compared to the group of patients with both macroscopic and microscopic myocardial infarction (Figure 1).

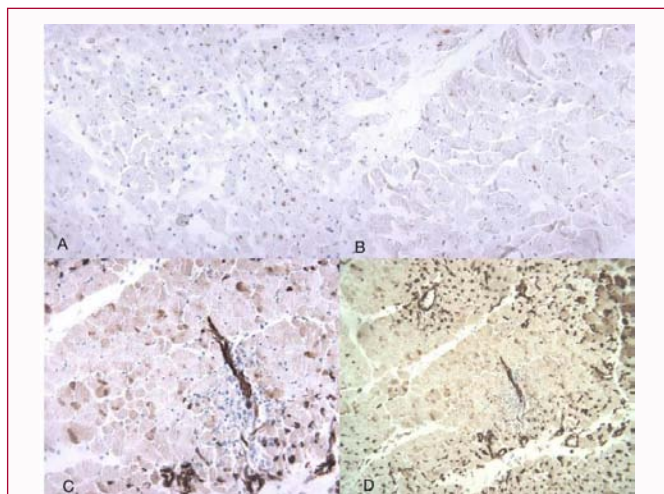
The reporting of the two study groups reveals a statistical and diagnostic importance. All 10 cases included in the control group did not show overexpression of the WT1 gene (score H=0).

**Table 1:** Characteristics of the patients included in the study.

	Acute myocardial infarction concordance	Acute myocardial infarction discordance
Cases	24	16
Age average	37.37	36.57
Age group		
<20 years	0	1
20-30 years	3	0
30-40 years	21	15
Female	2	2
Male	20	16
H-score average	135,625	74



**Figure 1:** Average value of the H score in patients with established acute myocardial infarction compared with patients with lack of macroscopically features of acute myocardial infarction and their differences with the value of the control group.



**Figure 2:** A) The image shows the extensive area of necrosis of the myocardial fibers with the low presence of WT1 nuclear expression (brown). B) Rare viable myocardial fibers showing WT1 nuclear aspects (brown). C) The image shows the presence of localized necrosis and myocardial cells in ischemic suffering. The nuclear/cytoplasmic expression of WT1 can be noted in a large number of cells (brown). D) Numerous myocardial cells affected by ischemia, showing in numerous cells the nuclear and cytoplasmic expression of WT1 (brown). Can be seen high expression of WT1 in endothelial cell.

The analysis of standard errors reveals a homogeneity of the lots included in the study. This fact ensures a statistical relevance of the results obtained.

Ischemia will induce at the level of endothelial cells a reactivation of WT1 expression in the marginal zone of acute myocardial infarction (Figure 2). Normally, this expression disappears after embryonic life.

## Discussion

About 90% of people affected by sudden cardiac death do not develop an acute myocardial infarction. People stabilized following a sudden episode (post resuscitation), even in the presence of ischemic heart disease, have normal troponin I and T values. However, arrhythmias have a pathological substrate that affects impulse conduction at the level of the ventricular myocardium. At autopsies, myocardial alterations, scars of old myocardial infarctions, left ventricular aneurysm, pathologies that can be associated with the triggering of an arrhythmia causing death are visible. However, there are also rare situations in which sudden cardiac death occurs in people with structurally normal hearts, in which the autopsy or the histopathological examination does not reveal any kind of pathology, which is why they are called white autopsies. The phenomenon is not rare. Studies show that in a fifth of sudden deaths, cardiac abnormalities can be identified [11].

In such situations, the pathologies suspected to be involved in triggering sudden episodes are channelopathies (long QT syndrome, Brugada syndrome, polymorphic ventricular catecholaminergic tachycardia) and genetic pathologies that affect the proteins of calcium, sodium and chlorine channels [5,6,12].

In our study, it is noted that in the case of patients with established acute myocardial infarction (more than 48 h from onset) as well as in the case of patients with severe ischemia or non-established myocardial infarction (less than 48 h), nuclear WT1 expression is present at myocyte level. WT1 expression is present in the angiogenesis process at the level of endothelial cells of blood vessels in the marginal zone of ischemia and hypoxia.

The expression of WT1 in the case of patients with macroscopic myocardial infarction reveals a much higher H score compared to the same expression in the case of patients with macroscopic non-constituted myocardial infarction.

Death occurring shortly after the onset of acute myocardial infarction raises major diagnostic problems in medical practice. The absence of obvious macroscopic infarct lesions can be associated with the omission of this diagnosis in the case of autopsies.

## Conclusion

WT1 expression is associated with the response of myocytes and endothelial cells in case of ischemia.

The use of immunohistochemical techniques to highlight the expression of WT1 can help in the final diagnosis of acute myocardial infarction in the case of deaths shortly after the onset of the disease. In the case of patients belonging to the forensic department, WT1 plays an important role in establishing with certainty the cause of death. A weak point of the study can be represented by the small number of cases.

## Acknowledgment

We thank to all Resident Laboratory staff for the entire technical support with the tissue processing and for providing WT1 immunomarker.

## References

1. Markwerth P, Bajanowski T, Tzimas I, Dettmeyer R. Sudden cardiac death - update. *Int J Legal Med* [Internet]. 2021;135(2):483-95.
2. Apetrei E. *Cardiologie Clinică*. Cuculici G, Gheorghiu A, editors. București: Editura Medicală Callisto; 2015. p. 599-62.
3. Finocchiaro G, Behr ER, Tanzarella G, Papadakis M, Malhotra A, Dhutia H, et al. Anomalous coronary artery origin and sudden cardiac death: Clinical and pathological insights from a national pathology registry. *JACC Clin Electrophysiol*. 2019;5(4):516-22.
4. Fan L, Yin P, Xu Z. The genetic basis of sudden death in young people - Cardiac and non-cardiac [Internet]. *Gene*. Elsevier B.V. 2022;810.
5. Goldblum JR, Lamps LW, McKenney JK, Myers JL. *Rosai and Ackerman's Surgical Pathology*. 11<sup>th</sup> Ed. Philadelphia: Elsevier; 2018.
6. Abbas A, Aster J, Vinay K. *Robbins and Cotran pathologic basis of diseases*. 10<sup>th</sup> Ed. Philadelphia: Elsevier Saunders; 2020.
7. Duim SN, Kurakula K, Goumans MJ, Kruihof BP. Cardiac endothelial cells express Wilms' tumor-1: Wt1 expression in the developing, adult and infarcted heart. *J Mol Cell Cardiol*. 2015;81:127-35.
8. Ventana.
9. Pop O, Bembea M, Pusta C, Pascalau A. Immune response in Squamous Cell Carcinoma (SCC): Tumor microenvironmental study. *Virchows Arch*. 2017;471(Suppl. 1):s118. [Google Scholar].
10. McCarty KS Jr, Miller LS, Cox EB, Konrath J, McCarty Sr KS. Estrogen receptor analyses: correlation of biochemical and immunohistochemical methods using monoclonal antireceptor antibodies. *Arch Pathol Lab Med*. 1985;109(8):716-21.
11. Schimpf R, Veltmann C, Wolpert C, Borggrefe M. Channelopathies: Brugada syndrome, long QT syndrome, short QT syndrome, and CPVT. *Herz*. 2009;34(4):281-8.
12. Libby P, Bonow R, Mann D, Tomaselli G, Bhatt D, Solomon S, et al. *Braunwald's Heart Disease A Textbook of Cardiovascular Medicine*. 12<sup>th</sup> Ed. Braunwald E, editor. Philadelphia: Elsevier; 2022.