



Dermatitis Artefacta: Retrospective Series of 32 Cases

Hali F^{1,2}, Rimaoui M^{1,2*}, EL Mokadem M^{1,2}, Chiheb S^{1,2}, Agoub M^{1,2} and Battas O^{1,2}

¹Department of Dermatology, Ibn Rochd University Hospital, Casablanca, Morocco

²Department of Psychiatric, Ibn Rochd University Hospital, Casablanca, Morocco

Abstract

Introduction: Dermatitis artefacta is the voluntary imitation, the induction of organic symptoms by a patient in order to manipulate others, especially the medical profession. It is a potentially serious psychopathological manifestation that is difficult to manage. The aim of our study is to illustrate the epidemiological and evolutionary characteristics of this factitious disorder through a series of cases.

Materials and Methods: We report a retrospective and descriptive study, covering a period of 10 years from 2010 to 2020. The exploitation data was provided from the medical archives.

Results: Our study concerned a cohort of 32 patients, the average age was 31.5 years. The sex ratio (M/F) was 0.1. The clinical analysis allowed us to identify a bullous lesion aspect (25%). The psychiatric examination revealed a depressive condition in 20 patients (62.5%). All patients were treated with occlusive dressings and appropriate psychological follow-up was adopted. After 6 months, a relapse rate of 58% was reported.

Discussion: Our study is one of the major series in the medical literature illustrating cutaneous pathomimia. It is a diagnosis of elimination. Presumptive arguments such as geometric lesions and lesions with sharp contours are often found, which is compatible with the results of the literature. Pathomimia can signify an "indirect call for help" about a situation of psychological difficulty. Multidisciplinary management is essential.

Introduction

The skin is particularly linked to the emotional, socio-affective and psychic life. The cutaneous pathomimia is a psychiatric pathology of variable expression focused on the body image. The patients then carry out an unconscious simulation of somatic manifestations [1]. In effect, the doctor finds himself in the situation where the patient narrates a vague and convoluted version of his medical history, self-harming and mimicking pathology to provide proof of the existence of the disease. Once the disease has occurred, he asks to be cured of a deliberately induced and maintained disease. Dermatitis artefacta has a significant impact on the health care system, and its recognition by general practitioners and non-psychiatric specialists is important in order to avoid unnecessary medical investigations. Medical education must provide clinicians with the conceptual and management frameworks necessary to understand and treat patients whose symptoms appear to be feigned. Future advances in management will benefit from an increased appreciation of the contribution of non-medical factors and greater awareness of findings from social neuroscience, occupational health and clinical psychology [2]. We report through a series of cases the different epidemiological and evolutionary aspects of dermatitis artefacta in the Moroccan context.

Materials and Methods

A retrospective and descriptive study of 32 patients in the dermatology department of the Ibn Rochd University Hospital in Casablanca for a period of 24 years, from January 1996 to June 2020. This method allowed the identification of 32 cases. The form was filled in using data from the medical files. The iconographic documents were elaborated after agreement of the patients. It included socio-demographic data (age, sex, patriarchal status, profession), medical and psychiatric history, reason for consultation, clinical description of skin lesions (elementary lesions, topography), triggering factors, mechanisms of self-induced lesions and type of psychological treatment. Follow-up data was collected following a consultation and/or telephone contact with the patients or the referring clinician. Dermatitis artefacta is then corresponding to self-inflicted lesions having as common characteristics a topography accessible to the patient, a well limited aspect of the lesions and geometrical contours. A skin biopsy was performed in case of diagnostic uncertainty and in order to rule out the various suggested diagnoses of an infectious, tumoral or vascular nature.

OPEN ACCESS

*Correspondence:

Maryem Rimaoui, Department of Dermatology, Ibn Rochd University Hospital, Casablanca, Morocco, E-mail: maryemrimaoui1@gmail.com

Received Date: 19 Dec 2022

Accepted Date: 09 Jan 2023

Published Date: 20 Jan 2023

Citation:

Hali F, Rimaoui M, EL Mokadem M, Chiheb S, Agoub M, Battas O. Dermatitis Artefacta: Retrospective Series of 32 Cases. *Clin Case Rep Int*. 2023; 7: 1460.

Copyright © 2023 Rimaoui M. This is an open access article distributed under the Creative Commons Attribution License, which permits unrestricted use, distribution, and reproduction in any medium, provided the original work is properly cited.

The diagnosis of certainty was established in consultation with the psychiatrists. Statistical analysis was carried out using SPSS software.

Results

Our study consisted of a cohort of 32 patients, the average age was 31.5 years with extremes of 11 and 58 years. Among our patients, we note the presence of one 9-year-old girl (3.13%) as well as 10 adolescent girls (31.25%) and 21 adults (65.63%). There was a predominance of females with a sex ratio (M/F) of 0.1. The average consultation time was 4 months with extremes ranging from 1 to 28 months. Eighteen patients (56.25%) reported a psychiatric history dominated by depression. The self-inflicted lesions occurred quite often after a triggering event: Death of a close relative, period of confinement, pregnancy, school difficulties or conflictual context. The management of our patients was hospital based in 25 patients (78.13%) and outpatient in seven cases (21.87%). The clinical analysis of the patients with pathomimia revealed multiple lesioned aspects (Table 1). The trunk and face are the most affected parts of the body with a percentage of 37.5% and 31.25% respectively, followed by the upper limbs (18.75%) and finally the lower limbs (12.50%) (Figures 1-4). Mucosal and lesions of the phanera were not reported. Lesions with sharp edges were found in 28 patients (87.5%) while geometric lesions were observed in 20 patients (62.5%) (Figure 5). In our series, the psychiatric examination revealed depression in 20 patients (62.5%), anxiety disorders in 5 patients (15.6%), psychotic disorder

Table 1: Clinical analysis of patients with skin pathomimia.

Type of basic lesions	Number of cases	Percentage
Bubbles	8	25.00%
Dyschromic scars	7	21.90%
Excoriation	6	18.80%
Erythema	6	18.80%
Ulcerations	4	12.50%
Erosions	3	9.40%
Crusted erythematous lesions	2	6.30%
Papulonodular lesions	2	6.30%
Necrosis	1	3.10%
purpura	1	3.10%
Atrophy	1	3.10%
Erythematous-Squamous lesions	1	3.10%

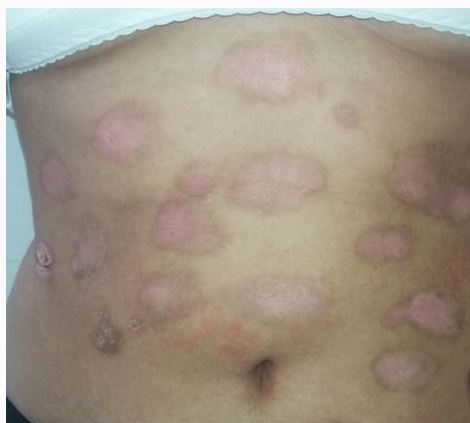

Figure 1: Geometric lesions with well-defined edges of dyschromic scars in the abdomen resulting from excessive deodorant application.

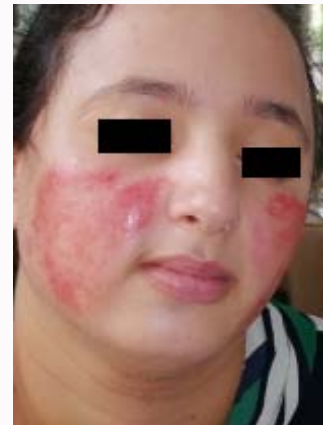

Figure 2: Erythematous lesions and well-limited erosions of the cheeks.

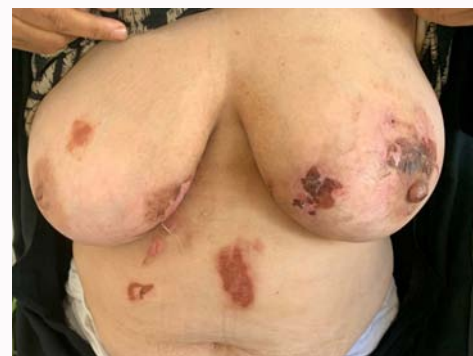

Figure 3: Erosive and pigmented lesions of the breast in the context of pathomimia.

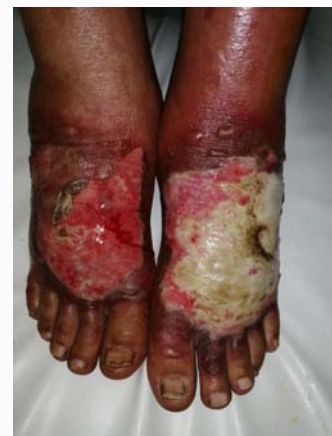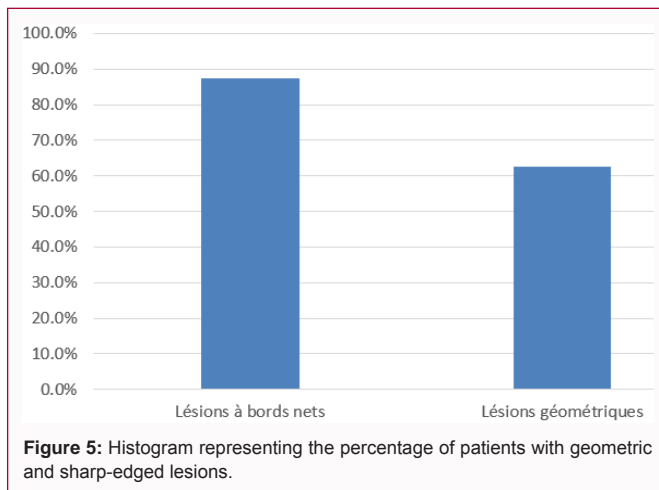


Figure 4: Well-limited ulcerated and fibrinous lesions on the dorsal surface of both feet.

in 4 patients (12.5%) and personality disorders in 3 patients (9.4%).

Histological examination was performed in 27 patients (84.37%) to exclude other suspected diagnoses. 100% of the skin biopsies were in favor of a non-specific dermatosis.

Therapeutic management consisted of a double approach, including dermatological treatment with occlusive dressings and topical healing agents, as well as treatment of superinfection when it existed and psychological treatment with appropriate medical therapy, whether or not associated with cognitive-behavioral therapy.



29 patients (90.48%) received medical treatment alone while 3 patients (9.52%) received cognitive-behavioral therapy.

Discussion

Dermatitis artefacta is defined as a factitious disorder voluntarily induced by the patient himself in a clearly conscious state. It is an intentional imitation of the induction of organic symptoms to the skin in order to manipulate health care staff [3]. The demographic profile of our sample shows a female prevalence. Data from several case reports support this hypothesis [4,5]. It generally affects young adults, as illustrated by our case series, and this is supported by several reviews. However, its occurrence in children is possible [6]. Factitious disorders often occur after a triggering factor such as pregnancy, the death of a close relative, difficulties in the workplace or at school, and even during a period of confinement following the COVID-19 pandemic. In this sense, a recent clinical case, like a patient in our sample, presented with multiple self-inflicted lesions excoriated by scratching [7].

By investigating the medical history of our patients, we found several clinical items often associated with factitious disorder in the literature, such as lesions with clear contours, often geometric, located in easily accessible areas, a sudden but unclear onset, an unexpected response to treatment, contradictory symptoms, an unclear biography, unexplained recurrences and finally a high tolerance for very prominent lesions. The data from our study show that the clinical presentation is considerably heterogeneous. Dermatitis artefacta presents in various semilogical forms depending on the patient and his creativity as well as the methods or tools he uses to produce these lesions. The clinical spectrum ranges from superficial erosions most frequently, to hyper- or hypo-pigmented lesions, excoriations, ulcerated lesions, necrotic lesions, purpuric lesions, up to a more advanced stage of crusts and scars. In our series, bullous lesions were observed in 8 patients out of 32 cases (22.2%), which is in fact the main manifestation observed in our study series. The bullous character was found to be the most frequent, in contrast to the literature, where bullous lesions has rarely been reported and can be induced by a variety of techniques. Histopathological examination can provide essential indices to support factitious origin such as vertical elongation of keratinocyte nuclei, often attributed to a polarization effect of the electric current, characteristic of electrical burns but can also be induced by thermal injury [8]. In contrast, necrosis and purpura are rarely seen in our sample and this is

consistent with the literature.

The mechanism of self-provocation of lesions can be a challenge. It is rarely reported, and may be the guideline towards confirmation of dermatitis artefacta. The typical example is the application of pigment which remains unexceptional [9].

Indeed, this heterogeneity partly explains the nomadism of patients with several doctors, the realization of several complementary examinations while remaining indifferent to the unfavorable evolution of repeated management [7]. Nomadism is at the origin of the underestimation of the prevalence of pathomimia, rare prevalence studies with heterogeneous results: 0.3% of patients hospitalized in neurology [10], 5.3% of patients with unexplained neurological disorders [11]. Some medical specialties, such as dermatology [12] are more familiar with factitious disorders, and some cases may concern surgeons, particularly plastic surgeons. A more accurate estimate of the prevalence of pathomimia must first be based on a better medical knowledge of this condition and close collaboration between general practitioners, non-psychiatric specialists and psychiatrists. To our knowledge, this is the first series in the literature illustrating pathomimia in the Moroccan context.

In terms of psychiatric comorbidities, our study shows a preponderance of depressive disorders. This result is perfectly consistent since the correlation between pathomimia and depression is frequently described in the literature [13]. There are many studies published in the literature that support these links, but the relationship between these diagnoses is still unclear. In this sense, the theory of the "Moi Peau" was developed by Didier Anzieu, a French psychoanalyst, in order to establish the metaphorical link between the real skin and a psychic structure that plays the role of a frontier between the interior world of the individual and the exterior world. The problem with patients suffering from dermatitis artefacta is that they experience their bodily and psychic limits as unreliable and are forced to attack their boundaries in order to, paradoxically (at least in appearance), ensure their solidity and reliability. It is important to note that pathomimia is a body image disorder and may be associated with eating disorders [14].

Psychiatric management is therefore imperative. The challenge is to manage the relationship between the doctor and the patient without brutally revealing to a patient that he or she is the author of his or her skin lesions; such an attitude is interpreted as an aggression on their internal psychic space.

Conclusion

Dermatitis artefacta can mean an "indirect call for help" with regard to a situation of psychological difficulty. Its prevalence remains underestimated given the nomadic nature of patients. A multidisciplinary approach and close collaboration between general practitioners, specialists and psychiatrists is therefore essential to treat these patients, contain them and relieve their anxieties and allow them access to verbalization of their suffering.

References

- Rizzi P, Guillier D, See LA, Roche M, Zwetyenga N. Pathomimia and plastic surgery, a case report. *Ann Chir Plast Esthet.* 2015;60(6):518-21.
- Bass C, Halligan P. Factitious disorders and malingering: Challenges for clinical assessment and management. *The Lancet.* 2014;383(9926):1422-32.
- Caselli I, Poloni N, Ielmini M, Diurni M, Callegari C. *Epidemiology and*

- evolution of the diagnostic classification of factitious disorders in DSM-5. *Psychol Res Behav Manag*. 2017;10:387-94.
4. Verraes-Derancourt S, Derancourt C, Poot F, Heenen M, Bernard P. Dermatitis artefacta: Retrospective study in 31 patients. *Ann Dermatol Venereol*. 2006;133(3):235-8.
 5. Rodríguez Pichardo A, García Bravo B. Dermatitis artefacta: A review. *Actas Dermosifiliogr*. 2013;104(10):854-66.
 6. Finore ED, Andreoli E, Alfani S, Palermi G, Pedicelli C, Paradisi M. Dermatitis artefacta in a child. *Pediatr Dermatol*. 2007;24(5):E51-6.
 7. Adebajo GAR, Parisella FR, Cittadini A, Luzi F, Tammaro A. A case of dermatitis artefacta during a pandemic. *Dermatol Ther*. 2020;33(6):e14235.
 8. Sokumbi O, Comfere NI, McEvoy MT, Peters MS. Bullous dermatitis artefacta. *Am J Dermatopathol*. 2013;35(1):110-2.
 9. Kumaresan M, Rai R, Raj A. Dermatitis artefacta. *Indian Dermatol Online J*. 2012;3(2):141-3.
 10. Bauer M, Boegner F. Neurological symptoms in factitious disorder. *J Nerv Ment Dis*. 1996;184(5):281-8.
 11. Kapfhammer HP, Dobmeier P, Mayer C, Rothenhäusler HB. Conversion syndromes in neurology. A psychopathological and psychodynamic differentiation of conversion disorder, somatization disorder and factitious disorder. *Psychother Psychosom Med Psychol*. 1998;48(12):463-74.
 12. Boyd AS. Revision: Cutaneous Munchausen syndrome: clinical and histopathologic features. *J Cutan Pathol*. 2014;41(4):333-6.
 13. Gil-Bistes D, Kluger N, Guillot B, Bessis D. Dermatitis artefacta in a young girl. *Arch Pediatr*. 2010;17(11):1543-5.
 14. Consoli SG. The "Moi-peau". *Med Sci MS*. 2006;22(2):197-200.