



Hyperviscosity Syndrome: A Rare Presentation of IgG Multiple Myeloma

Cristina P Martins*, Rita Reigota, Sandra D Santos, Diana L Gonçalves and Pedro M Ribeiro

Department of Internal Medicine, Coimbra Hospital and University Center - General Hospital, Coimbra, Portugal

Abstract

Hyperviscosity Syndrome (HVS) is an oncologic emergency that results from elevated blood viscosity. Hypergammaglobulinemia is the most common cause of HVS, especially monoclonal conditions involving IgM and rarely by IgG. HVS classically presents with the triad of neurological deficits, visual changes, and mucosal bleeding. Diagnosis is based on history and physical exam findings, in the setting of a potential causative disease. Eye examination is of particular importance, since it can prompt diagnosis and therefore treatment. HVS requires emergent treatment that consists of supportive therapy, plasmapheresis and control of the underlying cause. Plasmapheresis allows symptom relieve and must be initiated promptly.

We report a patient who presented with low back pain, fatigue, weight loss and that was found to have anemia, hypercalcemia, acute kidney injury, hyperproteinemia and multiple osteolytic lesions, that led to the diagnosis of multiple myeloma, later discovered to be of IgG type. On presentation, she also showed signs of gum bleeding and confusion, leading to diagnosis of HVS, after evidence of retinal hemorrhage on eye examination. Plasmapheresis was initiated, with improvement of HVS, but the patient died due to febrile neutropenia, after beginning of chemotherapy.

This case report describes a rare condition of HVS associated with IgG Myeloma. It highlights the importance of clinical suspicion to the diagnosis and the need for urgent treatment to control symptoms and prevent complications, since HVS represents an oncologic emergency that can lead to a multitude of organ failures if left undiagnosed and untreated, potentially compromising the patients' life.

Keywords: Hyperviscosity syndrome; Multiple myeloma; Plasmapheresis; Case report

Introduction

HVS is an oncologic emergency that results from elevated blood viscosity [1,2]. It can be caused either by a deformity of the shape of red blood cells or by any pathological elevation of cellular or acellular components of blood, particularly, immunoglobulins [1,3]. Hypergammaglobulinemia is the most common cause of HVS, especially the monoclonal condition of Waldenstrom Macroglobulinemia (WM), followed by myelomas, with the IgG type accounting for less than 5% of the cases [1,4]. We report the case of a patient with HVS in the setting of an IgG Multiple Myeloma, and the clinical challenges associated with the diagnosis and treatment of this medical entity.

Case Presentation

A 64-year-old woman presented to the emergency room with a history of low back pain, fatigue and weight loss with 6 months duration. Her husband also reported episodes of apathy and confused speech lasting 2 weeks. On presentation, her physical examination was unremarkable, except for the presence of pallor and gum bleeding (Figure 1). Her laboratory findings revealed a hemoglobin of 5.7g/dL (with normal MCV), hypercalcemia (Ca²⁺ 3.34 mmol/L), a creatinine of 1.21 mg/dL and a total protein value of 153 g/L with hypoalbuminemia of 21 g/L. The diagnosis of multiple myeloma was considered and a skull X-ray and lumbar CT were performed, showing a raindrop skull (Figure 2) and numerous osteolytic lesions, respectively, which confirmed our suspicion. Given the clinical picture, the diagnosis of HVS was also considered and assumed after the observation of retinal hemorrhage by an ophthalmologist. Plasmapheresis was immediately initiated and further laboratory, imaging and histologic studies were performed by Hematology, confirming the presence of: a monoclonal protein (Figure 3) of IgG type, multiple osteolytic lesions (on PET-CT) and a diffuse bone marrow infiltration of IgG kappa producing plasmocytes (on myelogram and bone biopsy).

OPEN ACCESS

*Correspondence:

Cristina Pereira Martins, Department of Internal Medicine, Coimbra Hospital and University Center - General Hospital, Coimbra, Portugal, Tel: +351 917965818;

E-mail: anacristinapm@hotmail.com

Received Date: 21 Jan 2021

Accepted Date: 16 Feb 2021

Published Date: 19 Feb 2021

Citation:

Martins CP, Reigota R, Santos SD, Gonçalves DL, Ribeiro PM. Hyperviscosity Syndrome: A Rare Presentation of IgG Multiple Myeloma. *Clin Case Rep Int.* 2021; 5: 1219.

Copyright © 2021 Cristina P Martins. This is an open access article distributed under the Creative Commons Attribution License, which permits unrestricted use, distribution, and reproduction in any medium, provided the original work is properly cited.

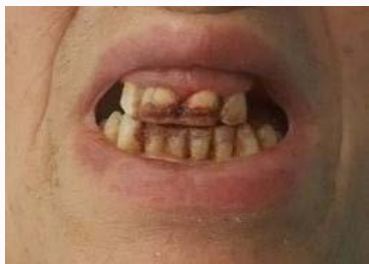

Figure 1: Gum bleeding in a patient with HVS.

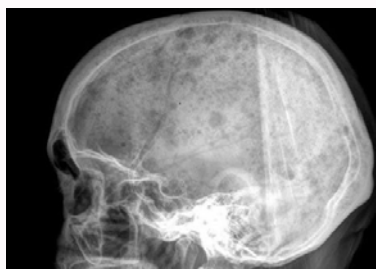

Figure 2: Skull X-ray (sagittal view) showing a raindrop skull, typical of myeloma.

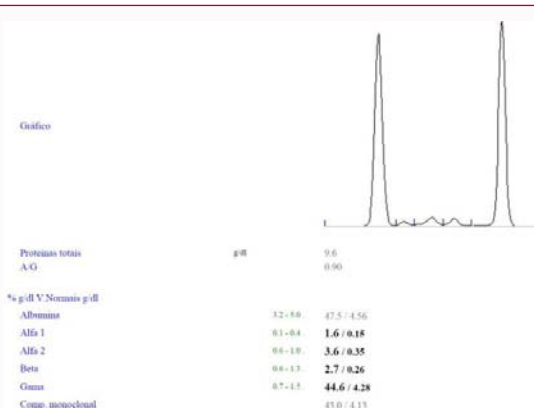


Figure 3: Serum protein electrophoresis showing an M-spike on gamma zone, suggestive of a monoclonal protein/gammopathy (later identified as of IgG type by immunofixation).

After 3 days of plasmapheresis, the patient showed signs of improvement of the HVS, with resolution of gum bleeding, retinal hemorrhage and neurologic deficits. She also started chemotherapy with Bortezomib, which also prevented further episodes of HVS, but eventually died of sepsis due to febrile neutropenia, after 2 months of treatment.

Discussion

HVS is an oncologic emergency that results from elevated blood viscosity [2]. The term viscosity refers to the internal resistance of a fluid to flow. HVS is the pathological condition in which blood flow is reduced due to an increase in its “thickness” [1,5]. It can be caused by a deformity of the shape of red blood cells (that occurs in diseases such as sickle cell disease and spherocytosis) or by any pathological elevation of the components of blood, either cellular (red blood cells, white blood cells, platelets) or acellular (serum proteins) [1]. Polycythemia vera, leukemia, and thrombocytosis are classic examples of diseases that can lead to an increase in blood viscosity due to an increase in the cellular components of blood,

whereas conditions that result in hypergammaglobulinemia (either monoclonal or polyclonal) are examples of diseases that increase blood viscosity due to an increase in acellular components of blood [1,3]. Polyclonal causes of HVS include rheumatoid arthritis, systemic lupus erythematosus, Sjogren syndrome compromise, Castleman disease and HIV infection. Monoclonal causes include myeloma, WM and cryoglobulinemia [1,2].

Hypergammaglobulinemia is the most common cause of HVS, particularly WM, because of the large star-shaped IgM pentamers that are highly viscous. Myelomas are the second leading cause, with IgA myelomas accounting for 25% of all HVS cases secondary to myelomas. IgG myelomas account for less than 5% of cases [4,6,7].

In terms of pathophysiology, an increase in blood viscosity decreases its flow, compromising the microvascular circulation, resulting in hypoperfusion of tissues. When hypergammaglobulinemia is involved, it can also impair platelet function, causing prolonged bleeding time [3].

Clinically, HVS classically presents with the triad of mucosal bleeding, visual changes, and neurological deficits. Bleeding, that results from affected platelet aggregation, is the most typical sign, being epistaxis, bleeding gums and gastrointestinal bleeding the most common sites of hemorrhage [1,3]. Visual changes and retinopathy can include blurred and/or double vision and arise from microvascular complications such as thrombosis or hemorrhage. Eye examination is paramount when HVS is suspected since it can lead to a timely diagnosis and allow a judicious treatment [1,2]. A reduced blood flow to the central nervous system and deposition of paraproteins within the myelin sheath of peripheral nerves result in neurological deficits, including headache, confusion, neuropathic syndromes, generalized stupor, coma, dizziness, ataxia, hearing impairment, seizures, and stroke syndromes [1,3,6].

Less commonly, a variety of end-organ damages can also be observed as the initial presenting symptom such as heart failure and myocardial infarction [1].

A high degree of clinical suspicion is required to diagnose HVS. Although laboratory evidence of high serum viscosity establishes the diagnosis, not all laboratories perform this test and, therefore, diagnosis of this medical entity is usually made based upon the clinical picture, when a potential cause is present or highly suspected [2,3]. Further testing should include a complete blood count, full serum chemistries, coagulation profile, and urinalysis [1,6].

Being an oncologic emergency, HVS requires prompt treatment in order to prevent catastrophic ischemia and multiple organ failure, and to reverse the signs, symptoms and complications associated with this condition [4,6]. Therapy should be based on the severity of signs and symptoms rather than the calculated degree of viscosity [1,4,6]. Initial treatment aims to control and ideally resolve the manifestations of HVS, while management of the underlying condition is planned and posteriorly initiated. Therefore, initial treatment of HVS consists of supportive therapy (particularly, hydration, since this condition results in high levels of dehydration) and plasmapheresis [6]. Plasmapheresis can promptly reverse most clinical manifestations of HVS, by decreasing serum viscosity by 20% to 30%. It is usually well tolerated and safe and can be done on a daily basis until clinical resolution of symptoms [1,5,6].

The definitive treatment of HVS involves chemotherapy for the underlying hematologic condition, and is commonly started

concomitantly, after observation and discussion of the case with Hematology/Oncology [6].

Conclusion

This case report describes a very rare condition of HVS associated with IgG Myeloma. It highlights the importance of clinical suspicion to the diagnosis and the need for urgent treatment to control symptoms and prevent complications.

The presence of HVS was highly suspected since our patient presented with gum bleeding and neurologic symptoms (history of confusion), and was later confirmed after the identification of retinal hemorrhage, that completed the classical triad of this condition, in the appropriate clinical setting of a newly diagnosed multiple myeloma. This effectively shows the importance of eye examination, when HVS is suspected, since it prompted the diagnosis and, therefore, the immediate initiation of plasmapheresis. This report also demonstrates the importance of rapid beginning of plasmapheresis to avoid further complications, particularly multiple organ failure due to ischemia, and to improve signs and symptoms. After multiple sessions of plasmapheresis, our patient's gum and retinal bleeding and confusion progressively resolved, and no other problems developed, which allowed the beginning of Bortezomib to treat the myeloma. Unfortunately, our patient presented with a severe and advanced form of multiple myeloma that resulted in her death due to complications associated with the disease and its treatment.

Our case is also interesting since there are few reports of HVS associated with IgG myeloma. This report alerts to the fact that this type of myeloma is also a potential underlying cause of HVS and this condition, if suspected, should not be ignored when an IgG related disease is present.

References

1. Rogers AP, Estes M. Hyperviscosity Syndrome. StatPearls Publishing 2020. (accessed January 2021).
2. Gertz MA. Acute hyperviscosity: Syndromes and management. *Blood*. 2018;132(13):1379-85.
3. Kwaan HC. Hyperviscosity in plasma cell dyscrasias. *Clin Hemorheol Microcirc*. 2013;55(1):75-83.
4. Mehta J, Singhal S. Hyperviscosity syndrome in plasma cell dyscrasias. In: Mammen EF, Kwaan HC, editors. *Semin Thromb Hemost*. 2003;29(5):467-71.
5. Gertz MA, Kyle RA. Hyperviscosity syndrome. *J Intensive Care Med*. 1995;10(3):128-41.
6. Mullen EC, Wang M. Recognizing hyperviscosity syndrome in patients with waldenstrom macroglobulinemia. *Clin J Oncol Nurs*. 2007;11(1):87-95.
7. Mackenzie MR, Fudenberg HH, Oroeyi RA. The Hyperviscosity Syndrome. In *IgG Myeloma. The role of protein concentration and molecular shape*. *J Clin Invest*. 1970;49(1):15-20.