



Median Nerve Injury After Brachial Artery Catheterization

Kara H^{1*} and Uzun K²

¹Department of Cardiovascular Surgery, Giresun Ada Hospital, Giresun, Turkey

²Department of Cardiovascular Surgery, Ahi Evren Thoracic and Cardiovascular Surgery Training and Research Hospital, University of Health Sciences, Trabzon, Turkey

Abstract

Median nerve injury developing after brachial artery catheterization is a rare and can lead to negative outcomes. This report presents the case of 72-year-old female who developed median nerve injury after brachial artery catheterization. She was treated with conservative treatment and physical therapy. This case highlights the potential for median nerve injury following brachial artery catheterization.

Keywords: Median nerve; Brachial artery catheterization; Peripheral nerve injury

Introduction

Due to anatomical proximity and hemostasis difficulties, nerve injuries are most commonly seen after axillary and brachial catheterization [1]. It results from direct needle trauma or haematoma or pseudoaneurysm compression, hemostasis devices, manual compression and ischaemia secondary to arterial occlusion. Clinical findings may vary from temporary minor pain to severe motor loss, depending on the degree of injury. Knowing the anatomy of the arm and forearm region, the use of smaller access needles, use of smaller sheaths, and ultrasound-guided access can reduce the risk of median nerve injury. We present a case of median nerve injury following brachial artery catheterization.

Case Presentation

A 72-year-old female patient presented to our department with complaints of pain, numbness, and weakness in her right-hand fingers after brachial artery catheterization. It was learned that a 2.5 mm × 16 mm drug-eluting stent was placed in the proximal part of the circumflex coronary artery of a patient who underwent percutaneous coronary intervention via the right brachial artery twenty days ago. Her medical history revealed that hypertension and dyslipidemia. Physical examination revealed weakness in the median nerve innervated muscles and edema in the right hand. There was no significant hematoma or pseudoaneurysm in the intervention location. Upper extremity arterial and venous doppler ultrasonography were normal. Furthermore, her laboratory tests revealed the following: white blood cell 7.55 cells/ μ L, hemoglobin 13.5 g/dL, haematocrit 40.8%, platelet 276.000/ μ L, glucose 92 mg/dL, sodium 141 mEq/L, potassium 4.9 mEq/L, blood urea nitrogen 39.9 mg/dL, creatinine 0.84 mg/dL, aspartate aminotransferase 18 IU/L, alanine transaminase 20 IU/L, total cholesterol 282 mg/dL, low density lipoprotein 154 mg/dL and triglyceride 154 mg/dL. Nerve Conduction Studies (NCS) and needle Electromyography (EMG) were consistent with median nerve injury. Medical treatment (Gabapentin, Diclofenac sodium, Amitriptyline) was performed upon the recommendation of the neurology clinic. Subsequently, Complex Regional Pain Syndrome (CRPS) was diagnosed, and physical therapy was performed for 6 months. The patient recovered without any sequelae.

Discussion

Nerve injuries following angiography and endovascular interventions can a distressing occurrence, both to the patient and the physician involved. The median nerve innervates the flexor muscles of the forearm and provides sensory innervation to the thenar muscles and the palmar surface of the first three and a half fingers [2]. The median nerve may be injured by needle trauma, compression or ischaemia secondary to brachial artery occlusion. Figure1 shows the anatomical proximity of the brachial artery and the median nerve. A study conducted recently by Destrieux, et al. [3] Brachial access site complications occurred in 9/251 patients (3,6%). In this study one case of severe nervous compression, leading to long-term neurological deficit up to 3 months postoperatively. There is no consensus on the use of the brachial artery for Appelt, et al. [4] Reported

OPEN ACCESS

*Correspondence:

Kara H, Department of Cardiovascular Surgery, Giresun Ada Hospital, Giresun, c28100, Turkey, Tel:00 90 532 3878690;

ORCID ID:0000 0002 5850 5920;

E-mail: hakankarakdc@hotmail.com

Received Date: 10 Dec 2025

Accepted Date: 21 Dec 2025

Published Date: 23 Dec 2025

Citation:

Kara H, Uzun K. Median Nerve Injury After Brachial Artery Catheterization.

Clin Case Rep Int. 2025; 9: 1746.

Copyright © 2025 Kara H. This is an open access article distributed under the Creative Commons Attribution License, which permits unrestricted use, distribution, and reproduction in any medium, provided the original work is properly cited.

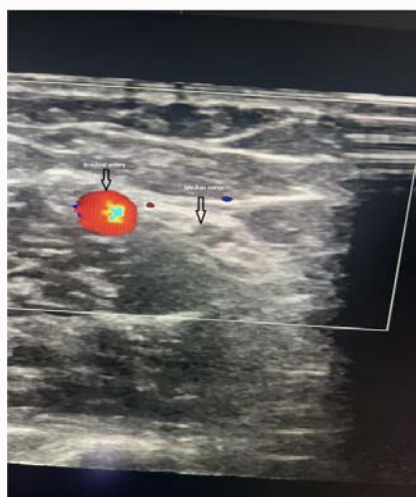


Figure 1: Colour doppler ultrasound view brachial artery with median nerve.

that sheath size was the only significant predictor of complications and puncture site complications were reduced with ultrasound-guided brachial puncture. Similarly, in a new study revealed that the rate of access site complications tended to increase with the size of the introducer sheath [3]. Traumatic injury to the median nerve causes sudden, severe pain radiating toward the hand [5]. Even after the needle or catheter is removed, complaints of pain, paresthesia or weakness may persist. The haematoma or pseudoaneurysm expands and compresses the median nerve. In these cases, symptoms do not appear suddenly but hours or days later. The presence of any post catheterization median nerve distribution deficits should promptly alert the physician to the possibility of median nerve injury so that the proper workup and treatment can be quickly initiated. Needle EMG and NCS can be helpful to diagnose. Acute neuropathic pain is managed with analgesics, tricyclic antidepressants, antiepileptic drugs, and systemic glucocorticoids [6]. Physical therapy is a very important part of treatment and should be started as soon as possible [7]. Haematoma is usually treated with manual compression, blood component treatment, or surgical evacuation [8]. In cases of compartment syndrome, fasciotomy should be performed immediately. Recently, methods other than surgery, such as ultrasound-guided compression, ultrasound-guided thrombin injection, biodegradable collagen injection, coil embolization, and placement of covered stents/ endoluminal prostheses have become popular for the treatment of pseudoaneurysms which develop after catheterization [9,10]. CRPS is a chronic neuropathic pain syndrome characterized by severe and long-lasting pain, typically occurring

after an injury or surgical intervention. CRPS treatment is performed to manage pain, prevent loss of function, and improve the patient's quality of life [11].

Conclusion

Median nerve injury may occur following brachial artery catheterization. It should be considered in complaints observed in the hand and forearm following brachial artery catheterization. Knowing the anatomy of the arm and forearm region, the use of smaller access needles, use of smaller sheaths, and ultrasound-guided access can reduce the risk of median nerve injury.

References

1. Kuo F, Park J, Chow K, Chen A, Walsworth MK. Avoiding peripheral nerve injury in arterial interventions. *Diagn Interv Radiol*. 2019;25(5):380-91.
2. Stretanski MF, Dydyk AM, Cascella M. Median Nerve Injury. 2025 Jul 7. In: StatPearls [Internet]. Treasure Island (FL): StatPearls Publishing. 2025.
3. Destrieux L, A.R.C.H.I.V. Group. Safety and Effectiveness of Ultrasound-Guided Percutaneous Versus Open Brachial Artery Access: Results of the Multicenter Prospective ARCHIBAL Study Percutaneous or Open Brachial Artery Access. *Ann Vasc Surg*. 2025;111:231-240.
4. Appelt K, Takes M, Zech CJ, Blackham KA, Schubert T. Complication rates of percutaneous brachial artery puncture: effect of live ultrasound guidance. *CVIR Endovasc*. 2021;4(1):74.
5. Tsao BE, Wilbourn AJ. Infraclavicular brachial plexus injury following axillary regional block. *Muscle Nerve*. 2004;30(1):44-8.
6. Gray P. Acute neuropathic pain: diagnosis and treatment. *Curr Opin Anaesthesiol*. 2008;21(5):590-95.
7. Kim HJ, Park SH, Shin HY, Choi YS. Brachial plexus injury as a complication after nerve block or vessel puncture. *Korean J Pain*. 2014;27(3):210-8.
8. Ortiz D, Jahangir A, Singh M, Allaqaband S, Bajwa TK, Mewissen MW. Access site complications after peripheral vascular interventions: incidence, predictors, and outcomes. *Circ Cardiovasc Interv*. 2014;7(6):821-8.
9. Petrou E, Malakos I, Kampanarou S, Doulas N, Voudris V. Life-threatening rupture of a femoral pseudoaneurysm after cardiac catheterization. *Open Cardiovasc Med J*. 2016;10:201-4.
10. Hanson JM, Atri M, Power N. Ultrasound-guided thrombin injection of iatrogenic groin pseudoaneurysm: Doppler features and technical tips. *Br J Radiol*. 2008;81:154-63.
11. Lima Pessôa B, Netto JGM, Adolphsson L, Longo L, Hauwanga WN, McBenedict B. Complex Regional Pain Syndrome: Diagnosis, Pathophysiology, and Treatment Approaches. *Cureus*. 2024;16(12):e76324.