



Multidisciplinary Approach to Scheduling Surgery for Diabetic Foot: A Case Report

Wang G, Wang L, Wang Y and Xu X*

Department of Chinese Medicine Surgery, Beijing Hospital of Traditional Chinese Medicine, China

Abstract

Background: The treatment of diabetic foot ulcers in this case is complex and multidisciplinary, and an interdisciplinary team is extremely beneficial.

Case Presentation: We performed the intervention on an old type 2 diabetes patient with poor health, whose left toes were severely necrotic. Surgery, including debridement and patella truncation, had positive effects on lower extremity circulation, infection control, cavity treatment, bone destruction, surgical debridement, recovery of foot function, and nursing. After five months, the patient's foot ulcer had healed, and walking function was preserved.

Conclusion: Scheduling interventional surgery and debridement are the key point in a complicated diabetic foot ulcers case, and multidisciplinary collaboration in treatment of diabetic foot is significantly important.

Keywords: Multidisciplinary collaboration; Diabetic foot ulcer; Timing; Interventional therapy

Introduction

In China, in 2010, the prevalence of diabetes was 11.6% [1], while the proportion of diabetic patients >50 years old with lower extremity arterial disease was 19.5% [2]; the proportion of diabetic patients >60 years old with lower extremity arterial disease was 35.4% [3]. The incidence of new foot ulcers in Chinese patients with diabetes during the period from 2010 to 2011 was 8.1%, and the incidence of new ulcers in patients with diabetic foot ulcers within that period was 31.6% [4]. Diabetic foot ulcers have gradually become a challenge in clinical therapy and a leading cause of hospitalization among patients with diabetes [5].

The medical community has reached a consensus in favor of multidisciplinary collaboration in treatment of diabetic foot [6-9]. The complexity of treatment for diabetic foot determines the importance of optimizing the timing of multi-disciplinary and sequential treatments. This case presentation describes a complicated process of treatment for an elderly patient with diabetic foot ulcers, who had signs of poor baseline physiology. The wounds healed, and foot function was maximally preserved.

Case Presentation

A 68-year-old man with 21-year history of type 2 diabetes presented with an ulcer on the left heel. Height was 162 cm; body weight was 69 kg; body mass index was 26.3. The patient had been diagnosed with lower extremity atherosclerotic obliterans 7 years earlier. The left lower limb has been numb for 6 years, with intermittent claudication and rest pain for 1 year. The patient reported that his sleep was affected, but his degree of pain was decreased with the intermittent use of analgesic agents. For the left lower limb with claudication, walking distance was 90 meters.

The patient was hospitalized on 10 July 2017. Twenty days before hospitalization, irritation and pain developed on the lateral skin of the toes of the left foot, with no obvious inducement. Purulent exudate was observed after skin ulceration, and the patient's body temperature increased to 39.5°C. During hospitalization, the five toes of the left foot were black, necrotic, and associated with aggravated rest pain. Although the dose of oral analgesics was increased, the patient's pain was not relieved, and his sleep was severely affected.

The patient's appearance on initial evaluation is shown in Figure 1A, 1B. The five toes of the left foot were almost entirely black and necrotic. The skin extending from the bottom of the foot to the 5th metatarsophalangeal joint was red and swollen, with obvious tenderness; skin temperature was

OPEN ACCESS

*Correspondence:

Xuying Xu, Department of Chinese Medicine Surgery, Beijing Hospital of Traditional Chinese Medicine, Affiliated to the Capital Medical University, No.23, Back Road of the Art Gallery, Dongcheng District, Beijing 100010, China,

E-mail: xxying7341@126.com

Received Date: 28 Jan 2018

Accepted Date: 01 Mar 2019

Published Date: 06 Mar 2019

Citation:

Wang G, Wang L, Wang Y, Xu X. Multidisciplinary Approach to Scheduling Surgery for Diabetic Foot: A Case Report. *Clin Case Rep Int*. 2019; 3: 1092.

Copyright © 2019 Xuying Xu. This is an open access article distributed under the Creative Commons Attribution License, which permits unrestricted use, distribution, and reproduction in any medium, provided the original work is properly cited.

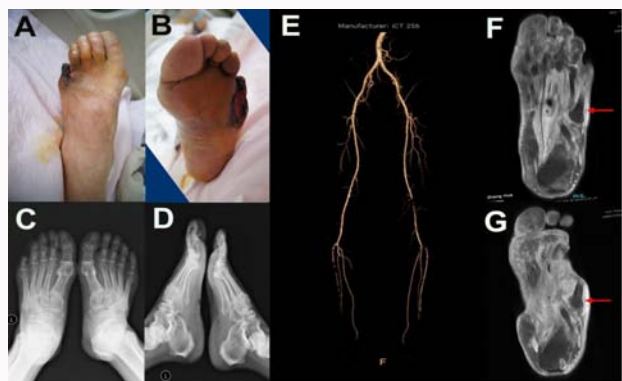


Figure 1A-1G: Diagnostic assessment of the diabetic foot ulcer.

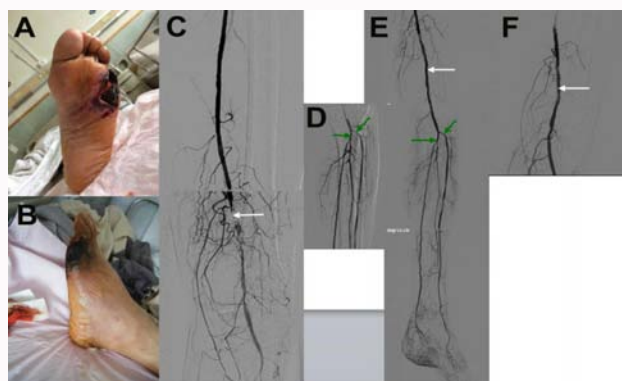

Figure 2A-2F: Administration of first therapeutic intervention.

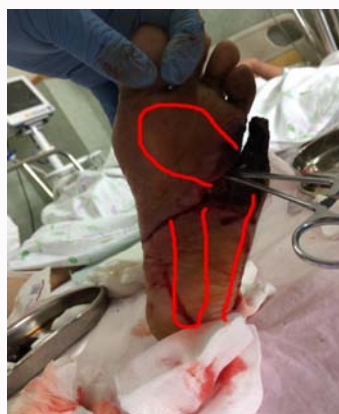

Figure 3: Subcavities found in the left foot.

normal. The muscles of the left foot had clearly atrophied; the skin was thin, bright, and hypertonic. Incision and drainage (approx. 5.0 cm long) was immediately performed between the 4th and 5th toes. Necrotic tissue, minimal purulent exudation, and limited bleeding were observed.

The diagnostic results on obtained on July 13 are shown. Secretion cultures displayed *Pseudomonas aeruginosa* and *Staphylococcus aureus*. X-ray film showed in Figure 1C, 1D revealed no obvious destruction in foot bone. The lower limb Computed Tomographic Angiography (CTA) is shown in Figure 1E.

The Magnetic Resonance Imaging (MRI) of the foot obtained on July 14th is shown in Figure 1F, 1G. Subcutaneous inflammatory

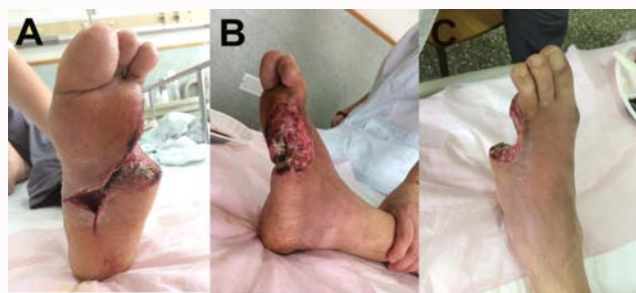

Figure 4: Results of patella truncation and debridement.

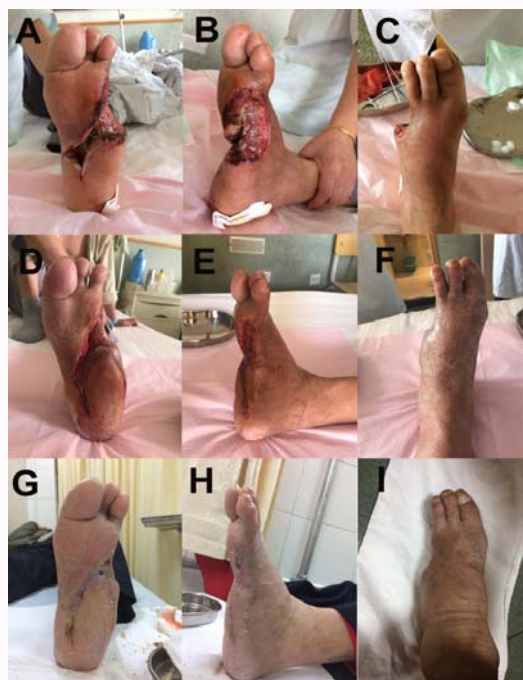

Figure 5A-5I: Follow-up of the surgical intervention and outcomes.

tissue in the lateral 5th humerus bone was confirmed as an infectious submerged cavity (Figure 3). The first incision performed at the bedside resulted in limited purulent exudation, as well as decreased local tension and reduced foot swelling. However, progressive necrosis of the skin margin was noted (Figure 2A, 2B).

On July 17, basal therapy consisted in controlling blood sugar with insulin (58 units/day). The initial antimicrobial application of ceftazidime infusion (2 gm, twice daily) was replaced by the sensitive drug Sulperazon (Cefoperazone Sodium and Sulbactam Sodium for Injection, Pfizer), according to the bacterial culture result of the secretion, and the application of antibiotics was stopped after July 22. The patient showed improved circulation and blood pressure. Treatment was maintained with protein and iron supplements.

On July 18th, interventional therapy was performed on the lower limb. The balloon was expanded in the superficial femoral artery, anterior tibia artery, iliac artery, and tendon. A thrombus had formed in the lower segment of the superficial femoral artery. The catheter for thrombolysis was left in place until July 20 (Figure 2C-2F). Skin temperature in the left foot increased, and swelling extended to the center of the foot. The amount of purulent exudation increased, as did pain and body temperature. The foot was therefore incised and

drained, once more. Multiple subcavities were found (Figure 3).

On July 21st, we performed patella truncation and debridement on toes 4 and 5. The procedure was performed in the operating room, with the patient under sciatic nerve block. Results are presented in Figure 4. Submerged cavities were filled with povidone-iodine gauze. The amount of nonviable tissue in the submerged cavity gradually decreased. The submerged space became shallow, and the granulation filled. All subsequent treatments were performed in the outpatient department.

From July 25th to September 30th, the left foot plaster was fixed at a functional position and applied intermittently (Figure 5A-5F). After October 1st, the plaster was removed. The patient was given diabetic shoes, and walking was guided. The first signs of wound healing were observed on November 19 (Figure 5G-5I).

Discussion

Debridement schedule

In order to minimize adverse effects, local debridement must be initiated in an expedient fashion. In the case presented above, the foot was severely ischemic and therefore could not support local blood transport after incision. In addition, infection easily spreads along the physiological cavity extending from the little toe. Efforts to avoid skin necrosis and wound expansion typically render comprehensive and meticulous debridement impossible.

After the initial treatment, we continued with nibbling debridement, in order to preserve as much residual tissue as possible. Debridement can be performed more thoroughly after blood transport is improved. The surgeon must continue to avoid over-injury, in order to restrict the area of infection. After the second episode of debridement [9], the opening of the cavity was patent and incompletely dissected (Figure 4). It is also possible to cut into the subcavities of the heel (Figure 5D-5G) and the lateral portion of the 5 tibia (Figure 5E-5H).

Intervention

Endovascular treatment may improve the blood supply to the lower limbs and create conditions conducive to thorough debridement and healing [10]. Such treatment should be initiated once the local infection is restricted, and the patient is stable. However, after the intervention, improved wound circulation increases the inflammatory response. In this case, the patient underwent substantial debridement during thrombolysis, when it was discovered that the infection had spread along physiological lacunae (Figure 3,4). Blood supply to the lower extremities was not considered sufficient for skin grafting.

Debridement

The term “nibbling debridement” denotes debridement that is gradual in spatial and temporal dimensions. Debridement is generally used to treat diabetic feet, which often have insufficient blood supply. The surgeons attempted to preserve as much tissue as possible, with the extent of debridement determined by guidelines for treatment during the infection, proliferative, and healing phases. The sites of debridement included: necrotic skin margins, fascia, deeper cavities, residual tendon and inactivated tissue in shallow lances, and hyperplastic granulation (during the later stages of treatment).

Preservation of foot function

In the early stage of treatment, it is necessary to fix the functional position in order to avoid supporting and walking. Such precautions

are necessary to avoid the flexion and extension of large joints. During the middle stages of treatment, joint activity may increase slightly. Once the plaster is fixed, the foot may be supported on the floor. However, walking should be forbidden, in order to avoid movement between tissues. During the latter stages of treatment, when healing is clearly underway, the patient should be given shoes tailored specifically for diabetic feet, to provide support during walking [11]. Training sessions to improve function of the lower extremities should be completed with increasing frequency, but the use of conventional shoes is prohibited.

Conclusion

The treatment of diabetic foot ulcers is extremely complicated. During the initial stages of diagnosis, a multidisciplinary team should make treatment recommendations based on the severity of ischemia and the degree of infection. If the foot cannot be preserved, thorough debridement may be performed during the initial stages of treatment to reduce adverse effects on the body. In combination with standard treatment, conditions for amputation should be achieved in as expedient a fashion as possible. Multi-disciplinary cooperation and optimization of the treatment schedule are necessary if there is even a remote possibility of preserving any portion of the foot or toes.

Declarations

Ethics approval and consent to participate

All procedures performed as part of this study were approved by the Ethics Committee of Beijing Traditional Chinese Medicine Hospital in Capital Medical University (No. 2015PBL-128). Informed consent was signed by the patient.

Funding

This study was supported by grants from the Beijing Municipal Administration of Traditional Chinese Medicine (No. WZF2012-13) and the National Natural Science Foundation of China (No. 81673975).

Acknowledgement

We seek to express our appreciation for contributions from Guangyu Wang, who coordinated management of the case and provided surgical expertise, and Leiyong Wang, who followed the patient and collected clinical data. All authors listed on the title page contributed to the collection of data collection and revision of the article.

References

1. Xu Y, Wang L, He J, Bi Y, Li M, Wang T, et al. Prevalence and control of diabetes in Chinese adults. *JAMA*. 2013;310(9):948-59.
2. Guan H, Liu ZM, Li GW, Guo XH, Xu ZR, Zou DJ, et al. [Analysis of peripheral arterial obstructive disease related factors among diabetic population aged > or = 50]. *Zhonghua Yi Xue Za Zhi*. 2007;87(1):23-7.
3. Wang AH XZ, Wang YH. Investigation on the increased lower extremity in the elderly diabetic patients with cardiovascular risk factors. *Geriatrics & Health Care*. 2005;11(3):147-9.
4. Jiang Y, Wang X, Xia L, Fu X, Xu Z, Ran X, et al. A cohort study of diabetic patients and diabetic foot ulceration patients in China. *Wound Repair Regen*. 2015;23(2):222-30.
5. Consensus Development Conference on Diabetic Foot Wound Care: 7-8 April 1999, Boston, Massachusetts. American Diabetes Association. *Diabetes Care*. 1999;22(8):1354-60.

6. Buggy A, Moore Z. The impact of the multidisciplinary team in the management of individuals with diabetic foot ulcers: a systematic review. *J Wound Care*. 2017;26(6):324-339.
7. Rubio JA, Aragon-Sanchez J, Jimenez S, Guadalix G, Albarracin A, Salido C, et al. Reducing major lower extremity amputations after the introduction of a multidisciplinary team for the diabetic foot. *Int J Low Extrem Wounds*. 2014;13(1):22-26.
8. Wilbek TE, Jansen RB, Jorgensen B, Svendsen OL. The Diabetic Foot in a Multidisciplinary Team Setting. Number of Amputations below Ankle Level and Mortality. *Exp Clin Endocrinol Diabetes*. 2016;124(9):535-540.
9. Mathioudakis N, Hicks CW, Canner JK, Sherman RL, Hines KF, Lum YW, et al. The Society for Vascular Surgery Wound, Ischemia, and foot Infection (WIFI) classification system predicts wound healing but not major amputation in patients with diabetic foot ulcers treated in a multidisciplinary setting. *J Vasc Surg*. 2017;65(6):1698-705.
10. Zil EAA, Shafi S, Ali MH. Think Before Chopping a Diabetic Foot: Insight to Vascular Intervention. *Cureus*. 2017;9(4):e1194.
11. Healy A, Naemi R, Chockalingam N. The effectiveness of footwear as an intervention to prevent or to reduce biomechanical risk factors associated with diabetic foot ulceration: a systematic review. *J Diabetes Complications*. 2013;27(4):391-400.