



## Recurrent Sinonasal Teratocarcinoma Treated with Surgery and Post-operative Intensity Modulated Radiotherapy (IMRT): A Case Report

JC Kenneth M. Jacinto\* and Michael Benedict A. Mejia

Department of Radiation Oncology, Benavides Cancer Institute, University of Santo Tomas Hospital, Manila, Philippines

### Abstract

**Background:** With only about a hundred published cases at this time, sinonasal teratocarcinoma is a rare disease managed definitively with surgery and adjuvant radiotherapy with concurrent chemotherapy. With no level I evidence, this management has been based on previous case reports, series and systematic reviews. At this time, there is no guideline on how to manage recurrent disease due to limited published cases, and decision on how to treat is extrapolated from management of paranasal carcinomas in general. This study reports a case of a 64 year-old male diagnosed with sinonasal teratocarcinoma who presented with recurrence to neck after 30 months post surgery and adjuvant radiotherapy.

**Case Presentation:** Patient initially presented with nasal obstruction and epistaxis. Rhinoscopy showed a mass on right nasal cavity that revealed teratocarcinoma on biopsy. Computed tomography (CT) scan showed mass on the sinonasal region. Patient underwent craniofacial resection followed by adjuvant radiotherapy to primary site via intensity modulated radiotherapy (IMRT). On follow-up at 30 months, the patient presented with biopsy proven recurrent disease in the neck. Radical neck dissection was done followed by adjuvant chemoradiation

**Results:** Patient is currently undergoing follow-up and surveillance with MRI. Two years on follow-up, patient presented with asymptomatic temporal lobe necrosis that was managed conservatively with watchful observation. Patient is asymptomatic and disease free for 8 years now.

**Conclusion:** Surgical resection with adjuvant radiotherapy with chemotherapy for presence of adverse risk features is reasonable treatment for recurrent sinonasal teratocarcinoma.

### Introduction

First coined in 1984 by Heffner and Hyams in a clinicopathologic study of 20 cases, teratocarcinoma (TCS) is a very rare malignant neoplasm of undetermined histogenesis with aggressive nature and poor prognosis [1,2].

At present, there are about a hundred reported cases worldwide with male to female ratio of 7:1–8:1 and the average age of diagnosis at 55–61 years old [3,4]. TCS is commonly located in the nasal cavity followed by the ethmoid and maxillary sinuses in 72%, 53% and 31% respectively. Sinonasal teratocarcinoma (SNTCS) frequently presents with nasal obstruction (75%) and epistaxis (63%). Other manifestations include frontal headache, neurologic, visual and olfactory disturbances and airway obstruction [3].

Previous studies on SNTCS have shown mean survival of 1.7 years and 3-year mortality rate of 30 to 60%. The 1-year recurrence rate is about 50% with median time to recurrence of about 7 months [5]. Due to its high malignant potential, behavior and low survival, the treatment for SNTCS brings great challenge to all fields of oncology. Aggressive multimodality treatment with surgery followed by radiotherapy with or without chemotherapy is believed to be the most optimal therapeutic approach [3]. Due to the rarity of this malignancy, no prospective and randomized controlled trials were done, thus no guidelines have been established. Up to this time, management is guided by systematic reviews and previous case reports.

We present a case of SNTCS treated with surgery and adjuvant radiotherapy to primary site that recurred with nodal disease after 30 months. This perhaps is the first reported case of SNTCS in the

### OPEN ACCESS

#### \*Correspondence:

JC Kenneth M. Jacinto, Department of Radiation Oncology, Benavides Cancer Institute, University of Santo Tomas Hospital, Manila, Philippines, Tel: +63 2 7313001;

E-mail: jc\_kenneth\_jacinto@yahoo.com

Received Date: 10 Jul 2017

Accepted Date: 21 Aug 2017

Published Date: 28 Aug 2017

#### Citation:

JC Kenneth M. Jacinto, Michael Benedict A. Mejia. Recurrent Sinonasal Teratocarcinoma Treated with Surgery and Post-operative Intensity Modulated Radiotherapy (IMRT): A Case Report. *Clin Case Rep Int.* 2017; 1: 1017.

**Copyright** © 2017 JC Kenneth M. Jacinto. This is an open access article distributed under the Creative Commons Attribution License, which permits unrestricted use, distribution, and reproduction in any medium, provided the original work is properly cited.

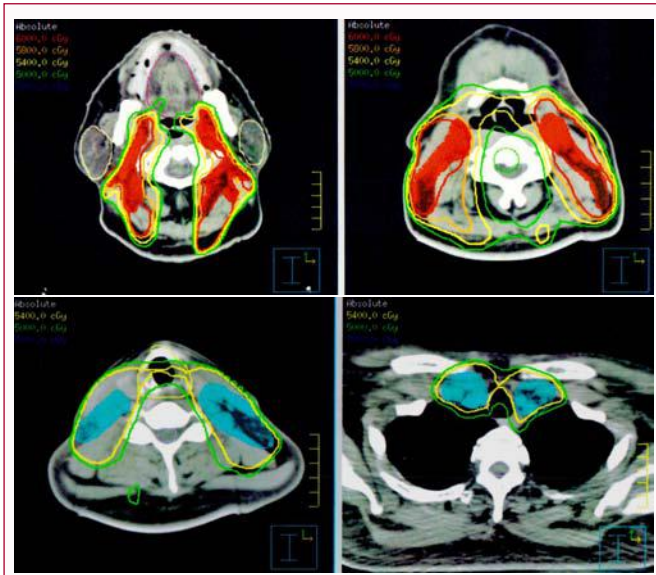


Figure 1A and 1B: Radiotherapy Isodose Lines.

Philippines and even in South East Asia.

**Case Presentation**

A 64-year-old man, from Manila, Philippines, with 20 pack-year smoking history, presented with one-month history of right nasal obstruction accompanied by recurrent ipsilateral epistaxis. On rhinoscopy, a slightly erythematous mass was noted completely obstructing the right nasal cavity. On physical examination, external ocular muscle movements full, all cranial nerves are intact and no other accompanying neurologic deficits. Complete blood count was done revealing normal hemoglobin at 12.4 mg/dl. Biopsy were done followed by immunohistochemical studies that showed (1) new ectodermal structures positive for chromogranin and synaptophysin, and negative for glial fibrillary acidic protein (GFAP), (2) epithelial structures positive for cytokeratin and epithelial membrane antigen (EMA), including squamous and glandular elements and (3) mesenchymal components positive for vimentin. Malignant germ cell was not present morphologically or immunohistochemically (Table 1). The diagnosis was teratocarcinosarcoma.

Paranasal sinuses computed tomography (CT) scan and magnetic resonance imaging (MRI) showed the residual right nasal cavity mass, measuring 5.4 cm × 3.8 cm, with infiltration to the right ethmoid sinus. There was no brain edema and cavernous sinus involvement. On positron emission tomography (PET) Scan, F18-fluorodeoxyglucose uptake was increased in the right nasal cavity (SUV 7.9) with normal uptake in the lymph nodes and throughout the body suggesting absence of metastatic disease. Patient had normal kidney and liver functions tests prior to any oncologic management.

Patient underwent craniofacial surgery and gross total resection followed by reconstruction. Pathology revealed 6.0 cm × 4.2 cm fragmented teratocarcinosarcoma of frontal, ethmoid and sphenoid sinuses with involvement of the respiratory mucosa, bone and soft tissue. Postoperative MRI of the brain and the nasal cavity revealed enhancement along the surgical packing in the ethmoid and frontal sinuses. Although this is expected, residual tumor cannot be ruled out. Five weeks post-surgery, patient underwent Intensity Modulated Radiation Therapy (IMRT) (Primus) to primary site using 6 mv photons, to deliver 60 Gy in 30 fractions (2.0 Gy/fraction). Clinical

Table 1: Patient’s immunohistochemistry results.

Immunohistochemistry Stains	Results
Chromogranin	+
Synaptophysin	+
GFAP <sup>1</sup>	-
Cytokeratin	+
EMA <sup>2</sup>	+
Vimentin	+
<sup>1</sup> Glial Fibrillary Protein, <sup>2</sup> Epithelial Membrane Antigen	

target volume (CTV) included post-operative bed. An expansion of 0.5 cm to CTV was added to create planning target volume (PTV), respecting anatomic barriers and organs at risk (OAR). OAR includes bilateral orbits, lens and optic nerves, brainstem, parotid gland, submandibular gland and oral cavity. Dose constraints were referred to the Quantitative Analyses of Normal Tissue Effects in the Clinic (QUANTEC) model.

Patient was followed-up regularly with physical examination, nasal endoscopy and MRI. Thirty months after treatment, an enlarged right submental lymph node was identified on palpation. On MRI, the mass was 2.2 cm × 1.8 cm in size. Fine needle aspiration biopsy was done that showed cytopathologic findings consistent with metastatic undifferentiated carcinoma. Radical neck dissection was done that showed metastatic TCS of right submandibular and submental lymph nodes with extra capsular extension. Metastatic work-up with PET scan post-surgery showed no focal hypermetabolic activity.

A multidisciplinary meeting was conducted with the consensus to give adjuvant chemoradiation. Patient received cisplatin 100 mg/m<sup>2</sup> every three weeks for three cycles concurrent with radiotherapy, to receive 60 Gy in 30 daily fractions via IMRT using 6 mv photons. CTV included cervical lymph node levels Ia, bilateral Ib, II and III, and 50 Gy in 25 daily fractions to the supraclavicular basin (Figure 1A and 1B). A 0.5 cm expansion to CTV was added to create PTV.

The patient completed and tolerated the treatment well, with grade 2 esophagitis and laryngitis that gradually resolved overtime. Physical examination, nasal endoscopy and MRI were done regularly on schedule for follow up. Until two years post re-irradiation, MRI revealed irregular mass at the right temporal lobe. Magnetic resonance spectroscopy (MRS) was done and showed slightly elevated choline/N-acetyl aspartate ratio with evidence of lipid peak compatible with presence of internal necrotic materials representing post-radiation temporal lobe necrosis. Patient was asymptomatic from the temporal lobe necrosis and no active management and observation was done.

As of the last follow up, 8 years from recurrence, the patient is well with no evidence of disease.

**Discussion**

Sinonasal TCS is a rare and aggressive malignancy with less than 100 cases reported worldwide up to this time [3]. Histologically, TCS is diagnosed by presence of malignant epithelial and mesenchymal components with immature neuroectodermal elements in the absence of germ cell components. Although not pathognomonic, 50%–75% has “fetal-appearing” squamous epithelium with clear cytoplasm. Immunohistochemistry also aid in arriving at the correct diagnosis [1,2].

While the nasal cavity and paranasal sinuses are the most

common sites of this malignancy, other cases have been reported in the oral cavity, orbit and the nasopharynx. SNTCS is very uncommon that tumors in these areas, and are misdiagnosed or lately diagnosed. More common differential diagnoses include non-neoplastic, benign and malignant lesions such as squamous cell carcinoma, lymphoma, esthesioneuroblastoma, neuroendocrine carcinoma, rhabdomyosarcoma, sinonasal undifferentiated carcinoma and other less common cancers [3,6].

Surgical resection is the first choice treatment for SNTCS however due to its anatomic location poses difficulty in achieving complete resection with adequate safety margin [7]. Surgery as the sole treatment had about 40% local recurrence rate suggesting its aggressive biologic nature and low survival [3,8]. This has proposed an aggressive initial therapeutic approach by adding adjuvant radiotherapy after radical surgical resection to offer best chance of disease free survival [9,10].

In a systematic review on the management of SNTCS, surgery followed by radiotherapy appears to be the most utilized treatment modality in 59.3% of the time. This has showed a lower local recurrence and distant metastasis with 26.1% and 10.9% as compared to surgery alone with 42.8% and 14.3% respectively [3]. The value of adding chemotherapy has been difficult to assess with the minimal number of patients who received trimodality treatment. This approach seems to improve outcome as it showed to have best survival and local control albeit small sample size [3,10].

In our case, the patient was treated with craniofacial and gross total resection followed by radiotherapy to primary site. Even after excellent craniofacial resection for paranasal sinus tumors, there is approximately 30% risk of cervical lymph node involvement for advanced ethmoidal sinus tumors hence necessitating to electively treating the neck. However, the morbidity of treatment to the bilateral neck in conjunction with primary site RT is high, and in the event failure, salvage surgery is possible, RT to primary site only was done.

The role of neck irradiation remains controversial in the management of sinonasal tumors. One case report recommended elective neck irradiation for sinonasal tumors due to the extensive lymphatic drainage and advanced presentation on diagnosis. This practice is based on the observation that most treatment failures are reported as local recurrences [11].

In a review of literature, recurrent disease is managed with surgery with or without radiotherapy and chemotherapy [10]. In recurrent disease or metastatic lesion, adjuvant chemotherapy may improve survival due to the presence of sarcomata components, pluripotent histology and rapidly growing biology [2,10,12].

Our patient presented with neck recurrence after 30 months and was managed with radical neck dissection. Due to presence of extracapsular extension, adjuvant radiotherapy via IMRT concurrent with high-dose cisplatin for 3 cycles was given. While adjuvant cisplatin plus etoposide doublet was another option raised by other medical oncologists, attending physicians believe that this will introduce more toxicity for a yet to be proven benefit. There is no strong evidence showing superiority of cisplatin plus etoposide in the adjuvant setting for head and neck cancers.

Due to difficulty in obtaining free surgical margins, high radiation doses are required to achieve local control benefit. With the proximity of sinonasal tumors to critical structures, use of less

contemporary radiotherapy techniques often results in suboptimal oncologic outcomes and worse toxicity [11,13]. IMRT has the capability to give concave and rapid dose fall-off distributions leading to higher dose to target volume while reducing dose to organs at risk to preserve organ function and improve quality of life. This technique can be used safely and effectively for nasal cavity and paranasal sinus malignancies [11,14-16].

Intensity modulated radiotherapy has been shown to have high local control rates and survival with lower radiation-induced toxicity and blindness for sinonasal tumors both in the primary and recurrent setting. There was no significant difference in outcomes among primary and recurrent tumors treated with post-operative IMRT suggesting better prognosis for locally recurrent disease treated curatively than usually thought [15,16].

## Conclusion

Surgical resection with adjuvant radiotherapy concurrent with chemotherapy for presence of adverse risk features (i.e. Positive margins and/or extracapsular extension) is a reasonable treatment for recurrent sinonasal teratocarcinoma.

## References

1. Heffner DK, Hyams VJ. Teratocarcinoma (malignant teratoma) of the nasal cavity and paranasal sinuses A clinicopathologic study of 20 cases. *Cancer*. 1984;53(10):2140-54.
2. Mondal SK, Mandal PK, Guha A, Roy S. Sinonasal teratocarcinoma of the ethmoid and paranasal sinus: A rare neoplasm. *J Res Med Sci*. 2012;17(6):575-7.
3. Misra P, Husain Q, Svider PF, Sanghvi S, Liu JK, Eloy JA. Management of sinonasal teratocarcinoma: a systematic review. *Am J Otolaryngol*. 2014;35(1):5-11.
4. Fatima SS, Minhas K, Din NU, Fatima S, Ahmed A, Ahmad Z. Sinonasal teratocarcinoma: a clinicopathologic and immunohistochemical study of 6 cases. *Ann Diagn Pathol*. 2013;17(4):313-8.
5. Budrukkar A, Agarwal JP, Kane S, Siddha M, Laskar SG, Pai P, et al., Management and clinical outcome of sinonasal teratocarcinoma: single institution experience. *J Laryngol Otol*. 2010;124(7):739-43.
6. Yang Z, Uppaluri R, Lewis JS Jr. Ethmoid sinus mass. Sinonasal teratocarcinoma. *JAMA Otolaryngol Head Neck Surg*. 2015;141(4):389-90.
7. Tokunaga T, Sunaga H, Kimura Y, Tsuda G, Fujieda S. A case of sinonasal teratocarcinoma treated with surgery and post-operative intensity-modulated radiotherapy (IMRT). *Auris Nasus Larynx*. 2012;39(6):641-5.
8. Sharma HS, Abdullah JM, Othman NH, Muhamad M. Teratocarcinoma of the nasal cavity and ethmoid. *J Laryngol Otol*. 1998;112(7):682-6.
9. Terasaka S, Medary MB, Whiting DM, Fukushima T, Espejo EJ, Nathan G. Prolonged survival in a patient with sinonasal teratocarcinoma with cranial extension. Case report. *J Neurosurg*. 1998; 88(4):753-6.
10. Wei S, Carroll W, Lazenby A, Bell W, Lopez R, Said-Al-Naief N. Sinonasal teratocarcinoma: report of a case with review of literature and treatment outcome. *Ann Diagn Pathol*. 2008;12(6):415-25.
11. Peng G, Ke Y, Wang T, Feng Y, Li Y, Wu G. Intensity-modulated radiotherapy for sinonasal teratocarcinoma. *J Huazhong Univ Sci Technol Med Sci*. 2011;31(6):857-60.
12. Sobani ZA, Akhtar S, Junaid M, Salahuddin I. Sinonasal teratocarcinoma. *J Pak Med Assoc*. 2012;62(6):633-5.
13. Itami J, Uno T, Aruga M, Ode S. Squamous cell carcinoma of the maxillary

- sinus treated with radiation therapy and conservative surgery. *Cancer*, 1998;82(1):104-7.
14. Daly ME, Chen AM, Bucci MK, El-Sayed I, Xia P, Kaplan MJ, et al. Intensity-modulated radiation therapy for malignancies of the nasal cavity and paranasal sinuses. *Int J Radiat Oncol Biol Phys*. 2007;67(1):151-7.
15. Duthoy W, Boterberg T, Claus F, Ost P, Vakaet L, Bral S, et al. Postoperative intensity-modulated radiotherapy in sinonasal carcinoma: clinical results in 39 patients. *Cancer*, 2005;104(1):71-82.
16. Madani I, Bonte K, Vakaet L, Boterberg T, De Neve W. Intensity-modulated radiotherapy for sinonasal tumors: Ghent University Hospital update. *Int J Radiat Oncol Biol Phys*. 2009;73(2):424-32.