



Renal Verrucous Carcinoma: A Very Rare Pathology Resolved by Partial Nephrectomy

Ibañez L^{1*}, Serrano A¹, De La Parra I¹, Martín J¹, Arévalo R¹, Barrera J², Cortés JA³, González-Peramato P⁴, Gómez A¹ and Moreno J¹

¹Department of Urology, University Hospital Clínico San Carlos, Complutense University, Spain

²Department of Radiology, University Hospital Clínico San Carlos, Spain

³Department of Pathology, University Hospital Clínico San Carlos, Spain

⁴Department of Pathology, University Hospital La Paz, Universidad Autónoma de Madrid, Spain

Introduction

Verrucous carcinoma is an unusual subtype of well-differentiated squamous cell carcinoma. Ackerman described it for the first time in the Otorhinolaryngology field in 1948 [1]. Verrucous carcinoma occurs most frequently in the nasal cavity, esophagus, vulva, vagina, anorectal region, penis, and skin. It is very rare in the urinary tract [1,2]. Very few cases of verrucous carcinoma have been reported in the bladder, mainly related to schistosomiasis infection. Renal verrucous carcinoma was first reported in a horseshoe kidney by Sheaff in 1996 [3]. To our knowledge, only six cases of verrucous carcinoma of the renal pelvis have been published previously; all of them were treated by radical nephrectomy or even nephroureterectomy [1-5]. In contrast, this case presents the first verrucous carcinoma in a renal calyceal diverticulum. Moreover, it was successfully treated by nephron-sparing surgery for the first time.

Case Presentation

A 60-year-old man with a clinical history of renal lithiasis was referred to our consultation of lithiasis due to small calculus located in the left kidney (Figure 1a, 1b). He was operated on for small calculi located in the lower calyceal diverticulum of the left kidney *via* Retrograde Intrarenal Surgery (RIRS) and micro-percutaneous (PNL). During the surgery, the calyceal diverticulum was accessed and multiple small calculi (2 mm to 3 mm) were removed. Methylene blue showed the existence of communication between the renal pelvis and the diverticulum, but direct endoscopic visualization was not possible. During the follow-up, a Magnetic Resonance Imaging (MRI) scan was performed (Figure 2a, 2b). A well-defined cystic lesion measuring 4.2 cm × 6 cm × 4.6 cm was observed in the posterior valve. The cystic lesion was mainly intrarenal with small eccentric growth. The MRI report described that the lesion could be a complicated calyceal diverticulum, without ruling out the coexistence of urothelioma or squamous tumor. After all, surgical resection of the lesion was decided. Through a subcostal incision, the left kidney was freed from the upper pole to the lower pole. The cystic tumor was identified at the posterior valve of the interpolar region. The lesion was removed without ischemia time. During the surgery, an opening of the diverticulum to the urinary tract was identified. The opening appeared to be a tubular structure communicating with the lesion with abundant cesium material coming out. The urinary tract was successfully closed. The patient had a favorable evolution at the hospital, presenting febrile peaks with negative cultures during the immediate postoperative period. He was discharged on the fifth postoperative day after a full course of antibiotics was completed.

The pathological study confirmed the existence of an exo-endophytic, acantholytic, papillomatous neoplasm composed of keratinizing squamous epithelium with mild atypia and expansive growth. The tumor focally invaded the medullary renal parenchyma in the form of small nests with increased cellular atypia and keratinization. The pelvic-calyceal epithelium was completely replaced. The renal parenchyma adjacent to the tumor shows signs of atrophy. The pathological diagnosis was a verrucous carcinoma with a focus on well-differentiated infiltrating squamous cell carcinoma (Figure 3). The margins were free of tumor.

Since the date of surgery, the patient has been followed up with imaging tests. A new Computed Tomography (CT) scan was performed every 3 months for the first 12 months. Then, a CT scan was done every 6 months and finally, an annual CT scan is being performed free of tumor recurrence in

OPEN ACCESS

*Correspondence:

Laura Ibanez, Department of Urology, University Hospital Clínico San Carlos, Complutense University, Madrid, Spain, E-mail: livemir9@gmail.com

Received Date: 06 Feb 2023

Accepted Date: 17 Feb 2023

Published Date: 21 Feb 2023

Citation:

Ibañez L, Serrano A, De La Parra I, Martín J, Arévalo R, Barrera J, et al. Renal Verrucous Carcinoma: A Very Rare Pathology Resolved by Partial Nephrectomy. *Clin Case Rep Int*. 2023; 7: 1486.

Copyright © 2023 Ibañez L. This is an open access article distributed under the Creative Commons Attribution License, which permits unrestricted use, distribution, and reproduction in any medium, provided the original work is properly cited.

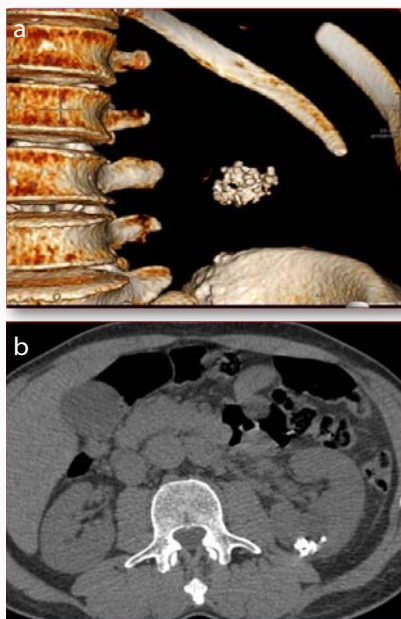


Figure 1: a) A 3D reconstruction of CT image. b) An Axial image of a basal CT. A cortico-subcortical cystic lesion of 3.5 cm with calcifications inside is described.

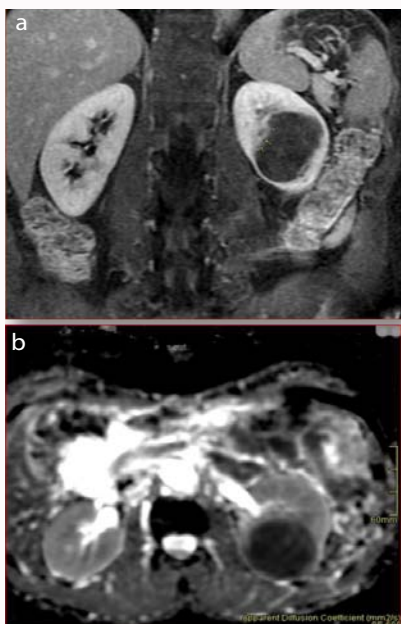

Figure 2: a) A Coronal image of T1 contrast-enhanced MR. A nodular thickening of the wall, suggestive of Bosniak IV cystic lesion is represented. b) An axial image of diffusion section (ADC) MR marked restriction of diffusion is observed which is characteristic of epidermal lesions.

the last 5 years (Figure 4). Adjuvant treatment has not been required.

Discussion

Verrucous carcinoma is a very rare subtype of squamous cell carcinoma. It is used to designate a specific histological appearance of well-differentiated squamous cell carcinoma [1]. It also shows extensive keratinization with exophytic or papillomatous extension into the stroma and the absence of significant cellular atypia [4]. Verrucous carcinoma occurs most frequently in the nasal cavity,

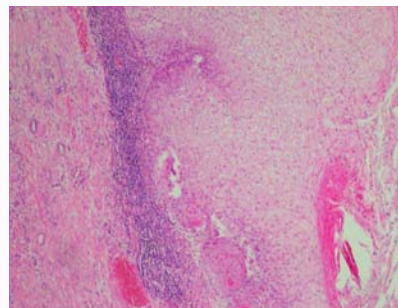


Figure 3: Microscopic image of the tumor. The replacement of the pelvic urothelium by a squamous epithelial proliferation with exophytic and endophytic growth with mild atypia is shown.

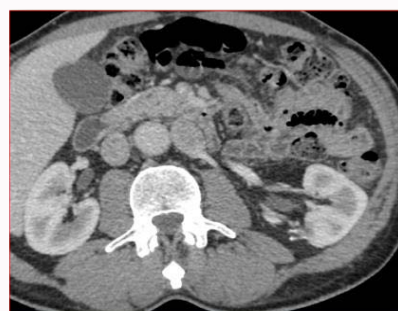

Figure 4: A CT image. Post-surgical changes on the left kidney with no signs of recurrence can be appreciated.

esophagus, vulva, vagina, anorectal region, penis, and skin. It is very unusual in the urinary tract [1,2]. Some risk factors include urinary tract infections, especially bilharziasis, or chronic inflammation, due to urinary lithiasis in 40% to 80% of cases; other factors include tobacco, coffee, phenacetin, and organic solvents [1]. All this leads to chronic irritation that causes squamous metaplasia which may eventually progress to carcinoma [1]. The average age of onset of verrucous carcinoma in urinary tract is about fifty-six years old; there is no predominance of men, unlike transitional cell carcinomas [1]. The clinical symptomatology is non-specific, patients mainly present with hematuria and occasionally lumbar pain [1]. Verrucous carcinoma has a good prognosis because of its characterization of local infiltration with a slight tendency to metastasize to regional lymph nodes or distant sites, unlike epidermoid carcinoma [3]. A few cases of verrucous carcinoma have been reported in the bladder related to schistosomiasis infection, but only six cases are described in the kidney (Table 1). Due to verrucous carcinoma may present extensive adjacent squamous metaplasia and coexistence with the squamous variant of carcinoma, a radical treatment was performed in previously reported cases [1-5].

To our knowledge, only six cases of verrucous carcinoma of the renal pelvis have been previously reported in the literature. In all these six cases, lithiasis may have been the cause of chronic inflammation. The average age at diagnosis has been fifty-five years old. Reviewing the cases reported in the literature about verrucous carcinoma in the renal pelvis previously, a higher prevalence in men than women can be found. None of the patients with verrucous carcinoma presented urinary tract anomalies, apart from the first patient who had horseshoe kidney [3]. In addition, in all cases published so far in the literature, the tumor was located in the renal pelvis [1-5] and only one case in pelvis and ureter [5]. The present case is the first one

Table 1: Patients with verrucous carcinoma of the renal.

	Age	Sex	Anomaly in tract urinary	Location of lesion	Treatment received	Outcome
Sheaff et al. [3]	41	M	+ (horseshoe kidney)	Renal pelvis	Heminephrectomy	6 months, NED
Sellami- Boudawara et al. [1]	61	M	-	Renal pelvis	Radical nephrectomy	5 years, NED
Sellami-Boudawara et al. [1]	56	M	-	Renal pelvis	Nephroureterectomy	Died
Kansal et al. [4]	64	F	-	Renal pelvis	Radical nephrectomy	2 years, NED
Basekioglu et al. [2]	56	M	-	Renal pelvis	Radical nephrectomy + RT + CT	3 years, Died
Hung WH et al. [5]	53	M	-	Renal pelvis and ureter	Nephroureterectomy +RT	3 months, NED
Present case	60	M	-	Calyceal diverticulum	Partial nephrectomy	5 years, NED

where a verrucous carcinoma was detected in a renal diverticulum. Moreover, the present case is the first one to be successfully treated with nephron-sparing surgery. All previously reported cases of verrucous carcinoma were treated by radical nephrectomy or even nephroureterectomy [1-5].

Partial nephrectomy surgery was revealed to be as effective as radical nephrectomy in patients with verrucous carcinoma without poor prognostic data (such as usual epidermoid carcinoma, poorly differentiated tumor, and affected surgical margins). In the cases of the previous studies where the patient died, positive surgical margins or poorly differentiated squamous cell carcinoma were present. These two features were related to the aggressiveness of the tumor. In spite of a radical nephrectomy being performed, both patients died of metastatic disease in the next few days after surgery [1,2]. None of the remaining cases presented any evidence of poor tumor prognosis, and a simple nephrectomy was performed successfully [3,4]. The present study is included in this second group, where characteristics of poor tumor prognosis were not present. It shows that a partial nephrectomy can be performed rather than a radical nephrectomy if there is no evidence of verrucous carcinoma aggressiveness characteristics.

In summary, the present case is the first report of verrucous carcinoma located in a calyceal diverticulum. It is also the first report of nephron-sparing surgery performed on a patient with verrucous

carcinoma with no poor prognostic factors. The patient has been free of disease for 5 years. However, there is not enough evidence to affirm that a nephron-sparing surgery treatment can be done in patients with verrucous carcinoma and the absence of poor prognosis factors instead of radical nephrectomy. More experience is needed to affirm that.

References

1. Sellami-Boudawara T, Gouiaa N, Makni S, Sellami A, Bahri I, Mhiri MN, et al. Carcinome veruqueux du rein; à propos de deux cas. *Ann Urol.* 2001;35(4):198-202.
2. Baseskioglu B, Yenilmez A, Acikalin M, Can C, Dönmez T. Verrucous carcinoma of the renal pelvis with a focus of conventional squamous cell carcinoma. *Urol Int.* 2012;88(1):115-7.
3. Sheaff M, Fociani P, Badenoch D, Baithun S. Verrucous carcinoma of the renal pelvis: Case presentation and review of the literature. *Virchows Arch.* 1996;428(6):375-9.
4. Kansal NS, Rosenberg G, Han M, Richter F. Verrucous carcinoma of the renal pelvis. *Urology.* 2001;58:105.
5. Hung WH, Chang A, Li Ch W, Liu CR, Leu JD. Verrucous carcinoma of the renal pelvis and ureter: A case report in Taiwan. *Therapeutic Radiol Oncol.* 2015;22(2):153-8.