



## Sinus Elevation for Implant Placement Leading to Implant Failure and Natural Tooth Extraction: A Case Report

Yingying Wu<sup>1,2</sup>, Zumu Yi<sup>1</sup>, Ting Gong<sup>1,2</sup>, Yili Qu<sup>1,3</sup> and Yi Man<sup>1,2\*</sup>

<sup>1</sup>Department of Oral Diseases, Sichuan University, China

<sup>2</sup>Department of Oral Implantology, Sichuan University, China

<sup>3</sup>Department of Oral Prosthodontics, Sichuan University, China

### Abstract

**Background:** Maxillary sinusitis has been considered as a major complication during sinus elevation surgery.

**Case report:** This case report presents an implant failure, persistent sinusitis and extraction of natural tooth that are caused by odontogenic infection during. A patient was treated with the simultaneous sinus elevation and dental implant placement for rehabilitation of the maxillary molar, which is adjacent to a natural tooth with intact root canal filling. Four months later, maxillary sinusitis was diagnosed reflected by nasal obstruction and foul-smelling discharge. The mobile implant was removed and replaced by a short implant without sinus elevation surgery. However, repeated symptoms of sinusitis was observed, which immediately healed after the extraction of natural tooth. Then the patient received implant insertion in the region of missing tooth, and no further complications were observed.

**Conclusion:** We proposed that sinus elevation stimulate the colonization of bacteria from the adjacent endodontically treated tooth, which lead to sinusitis and extraction of both implant and natural tooth.

**Keywords:** Peri-implantitis; Sinus floor elevation; Tooth extraction

### Abbreviations

CBCT: Cone Beam Computer Tomography; RBH: Residual Bone Height

### Introduction

Ever since it was first described by Tatum [1], and modified later by others, maxillary sinus floor elevation with grafting material has been proven to be a safe and highly predictable technique. Despite its high survival rate achieved with this augmentation technique, complications do occur, such as membrane perforation, postoperative sinusitis, cyst formation, wound dehiscence, sequestration, and loss of bone graft [2]. As a result of contamination of the maxillary sinus with oral flora [3], infectious complication during maxillary sinus-floor elevation procedure was observed in 9 out of 200 patients (4.5%) [4]. Other studies also demonstrated similar rate of infectious complication, which range from 3.5% to 4.3% [5,6]. Sinusitis is considered as a major complication because there is risk that the infection could spread throughout the graft and the sinus cavity or the adjacent anatomical structures [7].

Dental implant placements and dental extractions could be the iatrogenic causes for the occurrence of sinusitis. As the most common complication that occurs during sinus floor elevation procedures, perforations of the maxillary sinus membrane may results in direct communication between graft materials and sinus cavity, which can lead to infection and iatrogenic sinusitis. In addition, protruding and migration of dental implant into the maxillary sinus, blockage of air flow due to diminished intra sinus volume, ostium obstruction caused by postoperative swelling of the maxillary mucosa, and even the surgical procedures themselves have been reported to be the possible causes of sinusitis [8,9].

Odontogenic source is the other cause for cases of maxillary sinusitis, which can happen in people with maxillary teeth caries and maxillary dental trauma [10,11]. This case report presents an implant failure, persistent sinusitis and extraction of natural tooth that are mainly triggered by

### OPEN ACCESS

#### \*Correspondence:

Yi Man, Department of Oral Diseases, Sichuan University, West China Hospital of Stomatology, No.14, Sec.3, Renminnan Road, Chengdu 610041, Sichuan, China, Tel: +86-2885503579; E-mail: manyi780203@126.com

**Received Date:** 26 Nov 2019

**Accepted Date:** 26 Dec 2019

**Published Date:** 30 Dec 2019

#### Citation:

Wu Y, Yi Z, Gong T, Qu Y, Man Y. Sinus Elevation for Implant Placement Leading to Implant Failure and Natural Tooth Extraction: A Case Report. *Clin Case Rep Int.* 2019; 3: 1130.

**Copyright** © 2019 Yi Man. This is an open access article distributed under the Creative Commons Attribution License, which permits unrestricted use, distribution, and reproduction in any medium, provided the original work is properly cited.

sinus elevation and the intact root canal filling of natural tooth itself.

## Case Presentation

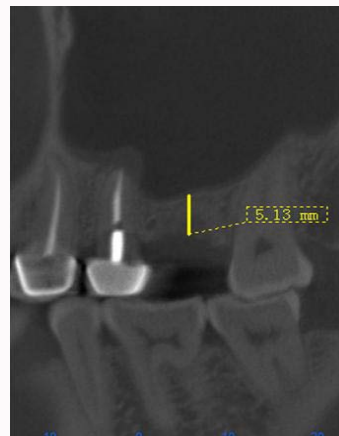
A 44-year old woman visited the clinic for reconstruction of the upper left first molar. Cone Beam Computer Tomography (CBCT) examination indicated that the Residual Bone Height (RBH) at the missing tooth region was about 5.13 mm, and no abnormalities of the sinus cavity was observed (Figure 1). The roots of upper left second premolar protrude into sinus cavity. Patients reported that the premolar received endodontic treatment that then received a post-core and porcelain-fused-to-metal crown several years ago.

The minimally-invasive transcresal sinus augmentation was performed using xenogenic graft (Bio-Oss, Geistlich Pharma); the vertical distance from sinus membrane to the alveolar crest was about 12 mm after the sinus elevation. Simultaneously, the implant (Osstem Implant Co., Busan, Korea, with 5 mm in diameter and 10 mm in length) was inserted with a good primary stability. However, four months later, the patient complained pain in the implant region, and nasal symptoms including nasal obstruction and discharge. Implant mobility was evident by intraoral observations. Thickening of sinus mucosa and large periapical radio lucency involving both the apical regions of the second premolar and dental implant were observed on CBCT images (Figure 2). Maxillary sinusitis was diagnosed by otorhinolaryngologist. We removed the mobile implant (Figure 3), performed lavages with sterile saline, and prescribed antibiotics. The symptom of nasal obstruction and discharge relieved along with the healing, with favorable evolution.

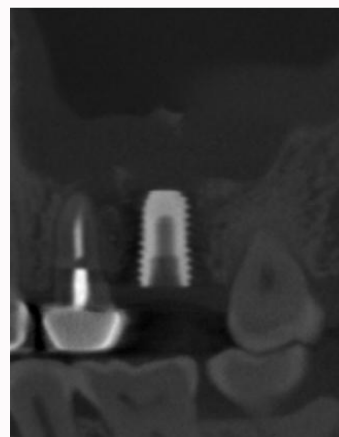
Six months later, only occasional nasal obstruction was reported by the patient, and no significant abnormalities were observed in the sinus based on CBCT examination. Progress appears to be satisfactory, so re-implantation treatment phase was initiated. We inserted a new implant with 5 mm in diameter and 8.5 mm in length (9 mm height of RBH at implant region was observed by CBCT measurement) without the surgery of sinus elevation (Figure 4). Then the patient was prescribed antibiotics for 3 days.

There was no pain or symptom of inflammation around the implant region during the healing process. Implant osseointegration was observed through radiographic examination three months postoperatively, and then the implant was restored by a full porcelain crown. Surprisingly, the patient returned complaining aggravated nasal obstruction and foul-smelling nasal discharge in one month. Objectively, thickened maxillary membrane and periapical radio lucency around the second premolar were observed on CBCT images. The patient received antibiotic therapy with amoxicillin and clavulanic acid for 1 week, but the symptom of sinusitis didn't show any improvement. We proposed that the sinusitis might be caused by the apical infection from the second premolar, which was then extracted. As it to be expected, the pain and nasal discharge subsided immediately after the tooth extraction.

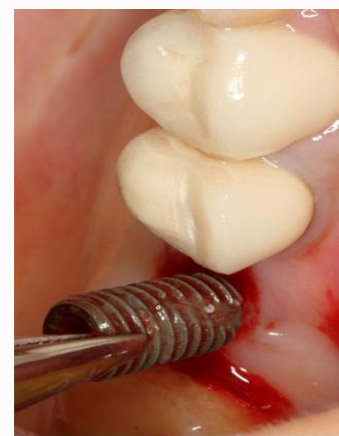The patient was clinically evaluated 1 month and 3 months after tooth extraction, absence of nasal obstruction and discharge was recorded. The post-surgery CBCT at 6 months showed complete resolution of maxillary sinusitis and 1mm thickness of sinus membrane. Then the implant (Bicon, America, 5 mm in diameter, and 8 mm in length) was inserted into the second premolar region (Figure 5). No further complications were observed, and the implant was exposed and restored as planned in 4 months (Figure 6). The patient received a follow-up examination every 3 months, and the



**Figure 1:** CBCT indicates 5.13 mm of the Residual Bone Height (RBH) at the missing first upper left molar before treatment.



**Figure 2:** Four months after implant placement surgery, CBCT examination showed significantly thickened sinus membrane and periapical radio lucency involving both the apical regions of the second premolar and dental implant.

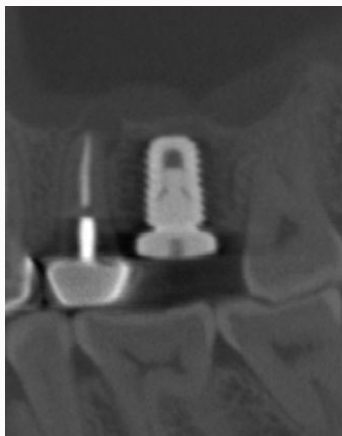


**Figure 3:** Implant removal was performed four months after placement.

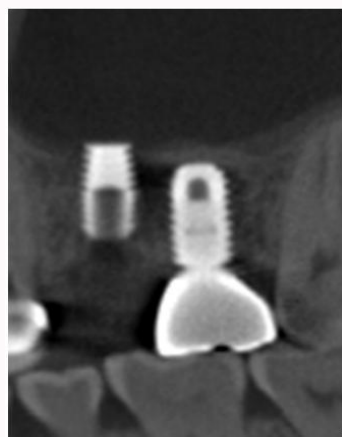
implant-supported fixed prosthesis has been functioning well for 18 months.

## Discussion and Conclusion

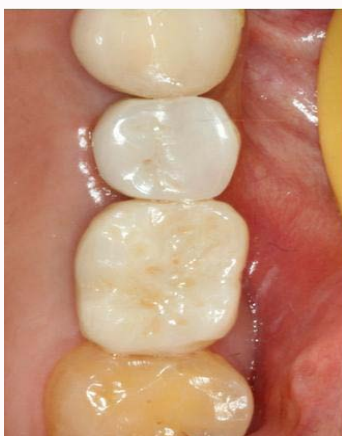Simultaneous sinus elevation and dental implant placement for rehabilitation of the maxillary molar was performed in this



**Figure 4:** A new implant with 8.5 mm in length was inserted into region where the implant was removed without the surgery of sinus elevation.



**Figure 5:** The implant was inserted 6 months after the extraction of the second premolar.



**Figure 6:** Cross-sectional image of the restoration of the upper left first molar and the upper left second premolar 4 months after the surgery.

case. However, maxillary sinusitis was observed and extraction of both implant and natural tooth was performed several months postoperatively. Although the incidence of sinusitis after sinus elevation is low, infection can have deleterious effects on graft and implant survival [9,12]. Among the different forms of sinusitis, the odontogenic form is very common, because the roots of premolars

and molars are close to the sinus cavity [13]. In this case, the root tips of the natural teeth (the second premolar) with root canal filling protrude into the sinus cavity. It has been reported that approximately 50% of endodontically treated teeth exhibited histologic signs of inflammation without any clinical symptoms [14,15]. And the residual bacteria in the asymptomatic endodontic treated tooth have the ability to colonize areas of significant tissue damage, which could be the situation adjacent to a newly placed implant [16-19].

In this case, to achieve the transcresal sinus elevation, the membrane had to be elevated from the sinus floor mesially and distally over the root tips of the adjacent teeth to become tension-free and thus to avoid any perforation of the membrane. So we proposed that the new environment created by sinus elevation may stimulate the colonization of bacteria from the adjacent asymptomatic endodontic treated tooth, result in the odontogenic infections penetrated into the maxillary sinus. Different from acute sinusitis, chronic sinusitis has always a bacterial etiology [13]. Amoxicillin with clavulanic acid was prescribed to resolve the symptoms, because it has been reported that this treatment reduces the bacterial load and the related mucosal inflammation [20]. But the sinusitis symptoms didn't get any improvement by the drug therapy with antibiotics. According to previous reports, it is very important to completely remove the cause of odontogenic sinusitis for a successful outcome [21]. As we expected, the patient reported an obvious improvement in nasal obstruction and a decrease in nasal discharge immediately after the extraction of the natural tooth. This further confirms that this natural tooth might be the odontogenic cause for sinusitis and implant failure.

In conclusion, even an asymptomatic endodontically treated tooth may be harboring chronic infection, which can spread to the apical region of implant through sinus. The elevation of sinus membrane involving both of the implant region and adjacent natural tooth received root canal treatment should be avoided if the roots of the tooth protrude into the sinus cavity. Otherwise, a short implant with minimal sinus elevation with a safe distance to the apical region of endodontic treated root could be an alternative option.

## Funding

This study was funded by the grant: The National Key Research and Development Program of China (No. 2016YFC1102700).

## References

1. Tatum H Jr. Maxillary and sinus implant reconstructions. *Dent Clin North Am.* 1986;30(2):207-29.
2. Lo Giudice G, Iannello G, Terranova A, Lo Giudice R, Pantaleo G, Cicciù M. Transcresal sinus lift procedure approaching atrophic maxillary ridge: a 60-month clinical and radiological follow-up evaluation. *Int J Dent.* 2015;2015:261652.
3. Misch CM. The pharmacologic management of maxillary sinus elevation surgery. *J Oral Implantol.* 1992;18(1):15-23.
4. Moreno Vazquez JC, Gonzalez de Rivera AS, Gil HS, Mifsut RS. Complication rate in 200 consecutive sinus lift procedures: guidelines for prevention and treatment. *J Oral Maxillofac Surg.* 2014;72(5):892-901.
5. Chirilă L, Rotaru C, Filipov I, Sandulescu M. Management of acute maxillary sinusitis after sinus bone grafting procedures with simultaneous dental implants placement - a retrospective study. *BMC Infec Dis.* 2016;16(Suppl 1):94.
6. Ferri J, Dujoncqoy JP, Carneiro JM, Raoul G. Maxillary reconstruction to enable implant insertion: a retrospective study of 181 patients. *Head Face*

- Med. 2008;4:31.
7. Urban IA Nagursky H, Church C, Lozada JL. Incidence, diagnosis, and treatment of sinus graft infection after sinus floor elevation. *Int J Oral Max Impl.* 2012;27(2):449-57.
  8. Kayabasoglu G, Nacar A, Altundag A, Cayonu M, Muhtarogullari M, Cingi C. A retrospective analysis of the relationship between rhinosinusitis and sinus lift dental implantation. *Head Face Med.* 2014;10:53.
  9. Katranji A, Fotek P, Wang HL. Sinus augmentation complications: etiology and treatment. *Implant Dent.* 2008;17(3):339-49.
  10. Lee KC, Lee SJ. Clinical features and treatment of odontogenic sinusitis. *Yonsei Med J.* 2010;51(6):932-7.
  11. Mehra P, Murad H. Maxillary sinus disease of odontogenic origin. *Otolaryngol Clin North Am.* 2004;37(2):347-64.
  12. Peleg M, Mazor Z, Garg AK. Augmentation grafting of the maxillary sinus and simultaneous implant placement in patients with 3 to 5 mm of residual alveolar bone height. *Int J Oral Max Impl.* 1999;14(4):549-56.
  13. Carini F, Longoni S, Amosso E, Carini S, Garavello W, Porcaro G. Odontogenic maxillary sinusitis with oro-nasal fistula: a case report. *Ann Stomatolo (Roma).* 2014;25:37-9.
  14. Seltzer S. Long-term radiographic and histological observations of endodontically treated teeth. *J Endod.* 1999;25(12):818-22.
  15. Rowe AH, Binnie WH. Correlation between radiological and histological inflammatory changes following root canal treatment. *J Br Endod Soc.* 1974;7(2):57-63.
  16. Shabahang S, Bohsali K, Boyne PJ, Caplanis N, Lozada J, Torabinejad M. Effect of teeth with periradicular lesions on adjacent dental implants. *Oral Surg Oral Med Oral Pathol Oral Radio Endod.* 2003;96(3):321-6.
  17. Tözüm TF, Sençimen M, Ortakoğlu K, Ozdemir A, Aydin OC, Keleş M. Diagnosis and treatment of a large periapical implant lesion associated with adjacent natural tooth: a case report. *Oral Surg Oral Med Oral Pathol Oral Radio Endod.* 2006;101(6):e132-8.
  18. Brisman DL, Brisman AS, Moses MS. Implant failures associated with asymptomatic endodontically treated teeth. *J Am Dent Assoc.* 2001;132(2):191-5.
  19. Shaffer MD, Juruaz DA, Haggerty PC. The effect of periradicular endodontic pathosis on the apical region of adjacent implants. *Oral Surg Oral Med Oral Pathol Oral Radio Endod.* 1998;86(5):578-81.
  20. Ferguson BJ, Narita M, Yu VL, Wagener MM, Gwaltney JM Jr. Prospective observation study of chronic rhinosinusitis: environmental triggers and antibiotic implications. *Clin Infec Dis.* 2012;54(1):62-8.
  21. Longhini AB, Ferguson BJ. Clinical aspects of odontogenic maxillary sinusitis: a case series. *Int Forum Allerge Rhinol.* 2011;1(5):409-15.