



## Spontaneous Splenic Rupture of a Patient Treated with Rivaroxaban

Hernandez A<sup>1\*</sup>, Ronquete M<sup>2</sup>, Perez R<sup>1</sup> and Vilas F<sup>2</sup>

<sup>1</sup>Department of Anesthesiology and Intensive Care, Grupo Policlinica, Spain

<sup>2</sup>Department of Surgery, Grupo Policlinica, Spain

### Introduction

Rivaroxaban is a novel anticoagulant and a direct factor Xa inhibitor that targets the prothrombin-binding site responsible for the conversion of prothrombin to thrombin. It is commonly used to lower the risk of stroke and systemic embolism in non-valvular atrial fibrillation and for the treatment of deep vein thrombosis and pulmonary embolism [1]. In addition, it has recently been approved by the US Food and Drug Administration (FDA) after the COMPASS trial, which showed a 24% risk reduction of major cardiovascular events in patients with chronic coronary artery disease and peripheral artery disease [2]. The most common adverse effect of Rivaroxaban is related to the increased risk of bleeding. We are reporting the sixth case of spontaneous splenic rupture caused by Rivaroxaban. Written permission to publish this case was obtained from the patient.

### Case Presentation

A 66-year-old gentleman with a background of hypertension and chronic atrial fibrillation, treated with Enalapril 20 mg (two times daily), Bisoprolol 5 mg (once a day) and Rivaroxaban 20 mg (once a day), was admitted to the Emergency Department with abdominal pain, nausea, and vomiting. He was a smoker but denied any alcohol intake.

On examination, he was tachycardic (115 bpm), hypotensive (BP 70/50 mmHg), had abdominal distention with tenderness in the epigastrium and left hypochondrium. Fluid resuscitation was commenced with crystalloids, and a Noradrenaline infusion was started via a PICC line (Peripherally Inserted Central Venous Catheter). Initial blood tests revealed Hemoglobin (Hb) of 11 g/dL with a normal platelet count (150,000/ $\mu$ L), and a coagulopathy [Prothrombin Time (PT) 43%, INR 1.93, activated Partial Thromboplastin Time (aPTT) 50 sec and fibrinogen 1.43 g/dL]. Arterial blood gas sampling confirmed metabolic acidosis (pH 7.22, PO<sub>2</sub> 93 mmHg and PCO<sub>2</sub> 35 mmHg) and a Computed Tomography (CT) of the abdomen/pelvis with intravenous contrast was undertaken, revealing a splenic rupture with a moderate hemoperitoneum (Figure 1A,1B). The patient reaffirmed there was no trauma prior to the onset of abdominal pain. A repeat full blood count was performed and confirmed a significant decrease in Hb (5.7 g/dL) and hematocrit (17.6%). Two units of Red Blood Cells (RBC) were transfused immediately, and the patient transferred to the operating room for emergency laparotomy and splenectomy.

An arterial line inserted prior to induction revealed severe hypotension (50/20 mmHg) requiring administration of small boluses of intravenous Adrenaline (5  $\mu$ g + 5  $\mu$ g). General anesthesia was initiated with a rapid sequence induction (Etomidate 18 mg, Fentanyl 150  $\mu$ g, Rocuronium 80 mg). Intubation was uneventful, and anesthesia was maintained with Sevoflurane and Remifentanyl. A percutaneous sheath introducer with a 8.5 French was inserted under US guidance into the right internal jugular vein to facilitate rapid administration of blood products. Four units of RBC and three units of Fresh Frozen Plasma (FFP) in addition to 500 mL of colloids and 500 mL of crystalloids were required during surgery aiming to stabilize the patient and reverse the coagulopathy. A total splenectomy was performed, and after safe extubation in the operating room, was transferred to the intensive care unit. His postoperative course was uneventful and successfully discharged home seven days later.

### Discussion

Rivaroxaban has a rapid onset of action with a relatively predictable pharmacokinetic profile and a relatively short plasma half-life making initiation, maintenance, and discontinuation of anticoagulant therapy considerably more comfortable than with traditional oral anticoagulants. It is highly protein-bound (92% to 95%) with renal excretion at 36%, and in contrast to other new anticoagulants as Dabigatran, dialysis is not effective for its removal.

### OPEN ACCESS

#### \*Correspondence:

Alberto Hernandez, Department of Anesthesiology and Intensive Care, Servicio de Anestesiología y Reanimación, Grupo Policlinica, C/ Vía Romana s/n, 07800 Ibiza, Islas Baleares, Spain, Tel: +34 971 30 19 16; Fax: +34971 30 17 56;

E-mail: albimar23@gmail.com

Received Date: 17 Jul 2019

Accepted Date: 15 Aug 2019

Published Date: 19 Aug 2019

#### Citation:

Hernandez A, Ronquete M, Perez R, Vilas F. Spontaneous Splenic Rupture of a Patient Treated with Rivaroxaban. Clin Case Rep Int. 2019; 3: 1115.

Copyright © 2019 Hernandez A. This is an open access article distributed under the Creative Commons Attribution License, which permits unrestricted use, distribution, and reproduction in any medium, provided the original work is properly cited.

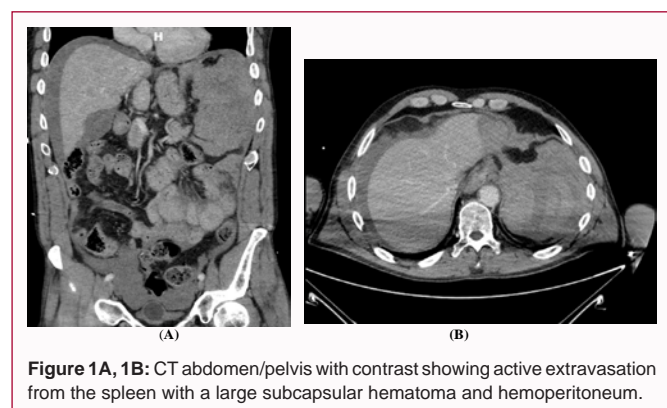
**Table 1:** Management of bleeding secondary to Rivaroxaban.

Rivaroxaban	Moderate bleeding: action	Severe bleeding: action
	<ul style="list-style-type: none"> <li>Fluid replacement.</li> <li>Give blood cells if Hb&lt;8 mg/dL</li> <li>Give platelets (if &lt;70,000/<math>\mu</math>L or if patient is taking an antiplatelet drug)</li> <li>Tranexamic acid iv (15-30 mg/kg) +/- continuous infusion (1 mg/kg/h)</li> <li>Consider Prothrombin complex 50 IU/kg, repeat if necessary<sup>*1</sup></li> </ul>	<ul style="list-style-type: none"> <li>Add recombinant factor VIIa (Novoseven® -100 <math>\mu</math>g/kg by IV bolus); repeat if necessary<sup>*2</sup></li> <li>Give Andexanet alfa if available<sup>*3</sup></li> <li>Bolus 800 mg at 30 mg/minute.</li> <li>Within 2 minutes following the bolus dose, administer the continuous iv infusion 8 mg/min for up to 120 minutes.</li> </ul>

<sup>\*1</sup>There is limited data available on the effectiveness of prothrombin complex in patients taking Rivaroxaban

<sup>\*2</sup>The effect of recombinant factor VIIa in patients taking Rivaroxaban is currently uncertain

<sup>\*3</sup>Half dose could be an option if there is no a life-threatening bleeding scenario



**Figure 1A, 1B:** CT abdomen/pelvis with contrast showing active extravasation from the spleen with a large subcapsular hematoma and hemoperitoneum.

In 2019 the update of the AHA/ACC/HRS in the guidelines for the management of patients with atrial fibrillation, Rivaroxaban is now recommended over warfarin for stroke prevention [3]. There is, at present, no consensus on the best methodology for assessing Rivaroxaban activity in vivo and hence no guiding dosage. Unlike traditional oral anticoagulants, traditional coagulation tests cannot be used to assess or adjust dosing. At therapeutic concentrations, Rivaroxaban has a relatively weak influence on the PT; however, it is more profound at higher concentrations, with a good correlation between prolongation of the PT and plasma concentration.

Although hemorrhage is the significant adverse effect of Rivaroxaban, unfortunately, there is no immediate reversal agent currently available. Although Andexanet alfa has been approved by the FDA, for reversal of anticoagulation in life-threatening or uncontrolled bleeding in patients treated with Rivaroxaban, it is not available in many countries. Therefore, other measures should be taken to treat significant hemorrhage (Table 1).

## Conclusion

Rivaroxaban's datasheet details no reference to spontaneous splenic rupture due to its use; however, this is the sixth case report of spontaneous splenic rupture in a patient, with no history of trauma, treated with Rivaroxaban.

A pharmacologic interaction could be the potential cause of an increase in activity of Rivaroxaban resulting in major hemorrhage. An interaction between amlodipine and telmisartan/hydrochlorothiazide

was reported as a cause of hemorrhage in a previous case report [4]. An interaction between amiodarone, a P-glycoprotein inhibitor and Rivaroxaban has also been reported as a cause of spontaneous splenic rupture [5].

It's well known that the higher risk of bleeding exists when Rivaroxaban is used in combination with antiplatelet agents, particularly in the elderly or in the presence of renal dysfunction. Specifically, of the case reports described previously one had aspirin as a potential cause and another reported renal dysfunction as the potential cause [6]. Similar to the case we are reporting, another could not ascertain a potential cause [7]. We believe there are significant numbers for the pharmaceutical manufacturer to mention splenic rupture in the datasheet and doctors need to be made more aware of this severe complication of patients prescribed Rivaroxaban [8].

## References

- ROCKET AF Study Investigators. Rivaroxaban-once daily, oral direct factor Xa inhibition compared with vitamin K antagonism for prevention of stroke and embolism trial in atrial fibrillation: rationale and design of the ROCKET AF Study. *Am Heart J*. 2010;159(3):340-347.
- Eikelboom JW, Connolly SJ, Bosch J, Dagenais GR, Hart RG, Shestakovska O, et al. COMPASS Investigators. Rivaroxaban with or without aspirin in stable cardiovascular disease. *N Engl J Med*. 2017;377(14):1319-30.
- January CT, Wann LS, Calkins H, Chen LY, Cigarroa JE, Cleveland JC Jr, et al. 2019 AHA/ACC/HRS Focused Update of the 2014 AHA/ACC/HRS Guideline for the management of patients with atrial fibrillation. *J Am Coll Cardiol*. 2019;74(1):104-132.
- Gonzva J, Patricelli R, Lignac D. Spontaneous splenic rupture in a patient treated with rivaroxaban. *Am J Emerg Med*. 2014;32(8):950.e3.
- Nagaraja V, Cranney G, Kushwaha V. Spontaneous splenic rupture due to rivaroxaban. *BMJ Case Rep*. 2018;2018. pii: bcr-2017-223237.
- Naseem Z, Mustaev M, Strekozov B. Spontaneous splenic rupture secondary to rivaroxaban: Rare but raising. *Int J Surg Med*. 2016; 2(3): 134-6.
- Yousef AH, Daniel S, Omar B. Rivaroxaban Causing Spontaneous Splenic Rupture, in C52. Illustrative disease presentations in critical care I: *Am J Respir Crit Care Med*. 2015;191:A4632.
- Amin A, Safaya A, Ronny F, Islam H, Bhuta K, Rajdeo H. Hemorrhagic Shock from Spontaneous Splenic Rupture Requiring Open Splenectomy in a Patient Taking Rivaroxaban. *Am Surg*. 2016;82(2):E54-5.