



The Development of *De novo* Acute Tubulointerstitial Nephritis and Membranous Nephropathy Following Inactivated COVID-19 Vaccine: Causal or Casual?

Zhao Y^{1#}, Zhang L^{2#}, Wang G², Guan J³ and Pai P^{2,4*}

¹Department of Microbiology, The University of Hong Kong-Faculty of Medicine, China

²Department of Nephrology, The University of Hong Kong-Shenzhen Hospital, China

³Department of Pathology, The University of Hong Kong-Shenzhen Hospital, China

⁴Department of Medicine, The University of Hong Kong-Faculty of Medicine, China

#Both the authors contributed equally to this work

Abstract

Acute tubulointerstitial nephritis is a common cause of hospital acquired acute kidney injury as part of a drug reaction, for instance after β -lactam antibiotics. Different types of COVID-19 vaccine-associated kidney diseases have been reported mostly following mRNA vaccine. The underlying mechanism remains unclear. Recently we treated 3 patients who developed acute tubulointerstitial nephritis and membranous nephropathy following COVID-2019 inactivated vaccine. We wish to share with others these potentially rare conditions and offer our experience in treatment.

Keywords: Coronavirus disease 2019; Inactivated vaccine; Membranous nephropathy; Acute tubulointerstitial nephritis

Introduction

To date, globally there are over 240 million confirmed cases of Coronavirus Disease 2019 (COVID-19) and over 4.9 million related deaths [1]. In face of this severe pandemic, active immunization becomes a major tool in the control of the COVID-19 pandemic [2]. Since the first case of COVID-19 infection was reported in December 2019 [3], 194 vaccines have gone through pre-clinical trials, and 128 vaccines are in clinical development stage worldwide [4]. With the increase in the number of vaccinations, nearly all approved vaccine types have been implicated in kidney diseases. Most cases have been related to mRNA-based vaccines, and both glomerular diseases [5-7] and Acute Tubulointerstitial Nephritis (ATIN) [8] have been reported. Here, we report 3 patients who received inactivated virus vaccination and went on and developed *de novo* Membranous Nephropathy (MN) in one patient and ATIN in the other two patients.

Case Presentation

Patient 1, a healthy 57-year-old woman, developed bilateral ankle edema the day after the first dose of inactivated COVID-19 vaccine. The edema resolved spontaneously within a few days, but reappeared after her second dose. On admission to the hospital, her sitting blood pressure was 112/67 mm/Hg and serum creatinine was 37 μ mol/L, albumin was 28.5 g/L, Immunoglobulin (Ig) G was 6.3 g/L. The urinalysis showed microhematuria 1+ and 1.6 g of proteinuria in 24 h. Both her serum and kidney biopsy were positive for anti-Phospholipase A2 Receptor (PLA2R) antibody. The biopsy showed MN. The renal pathology was illustrated in Figure 1. Secondary causes of MN, including specific drugs, infections and malignancy were excluded. After 4 weeks treatment with losartan, the patient's edema resolved although the proteinuria remained the same.

Patient 2 was a 53-year-old woman with a history of glucose intolerance on no treatment. One week after the first vaccination, she developed symptoms of fatigue, chest tightness and palpitation. These symptoms persisted after the second jab. She also developed urine froth and nocturia. On hospital admission, her serum creatinine was 322 μ mol/L. The urine analysis was negative for blood and there was \pm proteinuria. 24-h urine protein showed the presence of microalbumin at 69.9 mg. Total serum IgE was 2486 IU/ml. Two weeks after admission; the patient underwent a kidney biopsy. Her repeat serum creatinine was 357 μ mol/L. The result showed ATIN (Figure 2a) with negative Immunofluorescent (IF) staining. She was commenced on prednisolone at 0.5 mg/kg (total

OPEN ACCESS

*Correspondence:

Pearl Pai, Department of Nephrology,
The University of Hong Kong-Shenzhen
Hospital, Shenzhen, Guangzhou,
518000, China, Tel: +86-13632998552;
E-mail: ppai1@hku.hk

Received Date: 23 May 2022

Accepted Date: 07 Jun 2022

Published Date: 13 Jun 2022

Citation:

Zhao Y, Zhang L, Wang G, Guan J, Pai P. The Development of *De novo* Acute Tubulointerstitial Nephritis and Membranous Nephropathy Following Inactivated COVID-19 Vaccine: Causal or Casual?. *Clin Case Rep Int*. 2022; 6: 1344.

Copyright © 2022 Pai P. This is an open access article distributed under the Creative Commons Attribution License, which permits unrestricted use, distribution, and reproduction in any medium, provided the original work is properly cited.

Table 1: Case characteristics.

	Age/ Sex	Past medical history	Vaccine type; manufacturer	Days from vaccination to onset	Relapse after 2 nd dose, if given	Presentation	Kidney biopsy (Pathology diagnoses)	Treatment	Outcome
Patient 1	51/F	Healthy	Inactivated COVID-19 Vaccine, from Sinovac	1 day	Y	NS	MN	ARB (Losartan)	PR
Patient 2	52/F	Abnormal glucose tolerance	Inactivated COVID-19 Vaccine, from Sinovac	7 days	Y	AKI	ATIN	Cs (Prednisolone 0.6mg/Kg)	CR
Patient 3	37/F	Hashimoto thyroiditis	Inactivated COVID-19 Vaccine, from Biokangtai	14 days	N	AKI	ATIN	Cs (Prednisolone 1mg/Kg)	CR

KB: Kidney Biopsy; MN: Membranous Nephropathy; ATIN: Acute Tubulointerstitial Nephritis; ARB: Angiotensin II Receptor Blocker; Cs: Corticosteroids; PR: Partial Remission; CR: Complete Remission

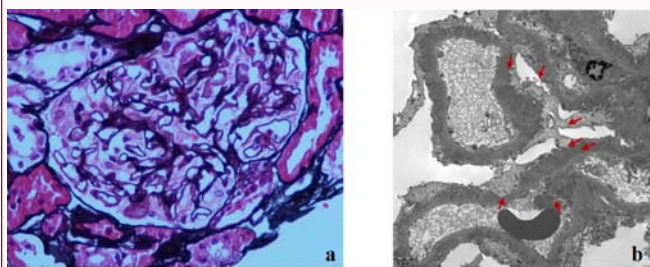


Figure 1: a). Basement membrane of glomerular capillary loop is thickened and stiff, vacuolar degeneration can be seen, and specific spikes can be seen in some segments. (Hematoxylin and eosin stain, x400); b). Some spikes were observed under electron microscopy (red arrows).

30 mg). Five weeks later, her serum creatinine fell to nearly normal.

Patient 3 was a 37-year-old woman. She was admitted to our hospital following a week history of abdominal distension, acid reflux and bilateral loin pain after receiving inactivated COVID-19 vaccine. On admission, she was found to have a serum creatinine of 195 $\mu\text{mol/L}$ with hematuria 2+ and proteinuria 2+. The same patient was also found to have a mild thyroiditis on biochemical and immunology assay and an anti-nuclear antibody ANA of 1 in 320. A kidney biopsy showed ATIN (Figures 2b-2d) with negative IF staining. She was treated with prednisolone at 1 mg/kg (55 mg in total) which was tapered off gradually. At her follow-up visit 3 months later, her serum creatinine had returned to near normal. The main characteristics and laboratory test results of the 3 patients are shown in Table 1, 2.

Discussion

As the worldwide hospitalization rate and mortality rate are reduced through intensive and extensive vaccination on an international scale, the safety and effectiveness of COVID-19 vaccines have drawn more public attention. Recently, there have been some reports about the development of *de novo*/relapse/worsening kidney diseases after COVID-19 vaccination. However, this is not the first-time vaccine has been implicated in kidney diseases. Influenza vaccine [9] and tetanus-diphtheria-poliomyelitis vaccine [10] have been reported to induce Minimal Change Disease (MCD). One study found viral RNA in inactivated influenza vaccines that might have contributed to the development of Anti-Neutrophil Cytoplasmic Antibody (ANCA)-associated vasculitis [11]. But the mechanism of these vaccine-associated diseases remains unclear.

Inactivated COVID-19 vaccines should be the safest [12,13] among all different vaccine types. Inactivated vaccines generally destroy the nucleic acid component of the virus rendering the virus non-infectious through physical or chemical methods. Therefore, only complete or partial virus particles with or without adjuvant are present in the vaccine. The immunogenic mechanism of inactivated

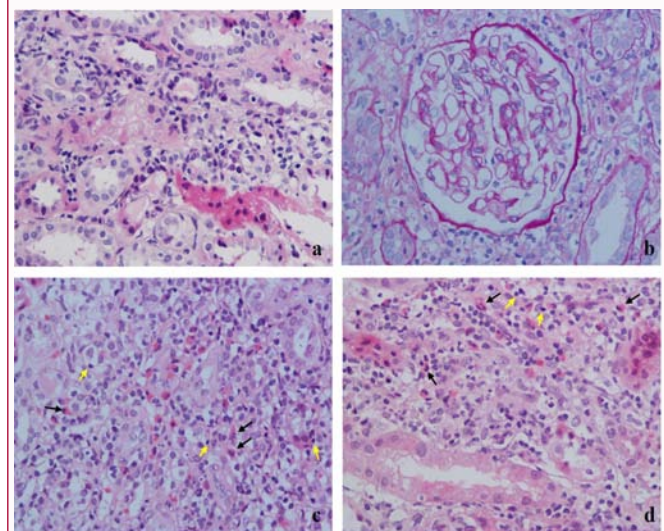


Figure 2: a, b). No obvious injury of glomerulus was found. c, d). There are eosinophils (black arrows) and lymphocytes infiltration (yellow arrows). There are slight tubular atrophy and fibrosis in interstitium (hematoxylin and eosin stain, x400).

vaccines depends on the stimulation of T helper type 1 (Th1)-based T-cell responses and production of Receptor-Binding Domain (RBD)- specific binding antibody and neutralization antibodies to provide protection [14]. However, Th1 cells have also been described as the pathogenic subset that might contribute to the development of organ-specific autoimmune diseases [15].

None of the 3 patients reported here were known to have past history of kidney disease or autoimmune disease. There may be a causal relationship between the vaccine and patient 1's MN, because of the temporal relationship between the onsets of the PLA2R associated membranous nephropathy. We hypothesize that certain component in the vaccine may trigger a loss of tolerance to the PLA2R antigen on the podocyte, which ultimately leads to *de novo* MN. Patient 2 and 3 appeared to have positive ANA which would suggest they might carry a predisposition to immune-mediated disease. The immune response caused by inactivated vaccine or adjuvant may induce the development of *de novo* ATIN in such highly sensitive patients. We speculate that some components of the inactivated COVID-19 vaccine might induce abnormal regulation of the immune system in susceptible individuals, and lead to these new-onset kidney diseases. However, further studies are needed to elucidate the exact mechanisms in these conditions.

After the initial therapies, all 3 patients developed symptomatic relief and a favorable outcome. We believe that the renal sequelae of the inactivated vaccines are limited, and our treatment may be used

Table 2: Laboratory finding on admission.

	Patient 1	Patient 2	Patient 3	Reference interval
Urinalysis				
Gravity	1.024	1.01	1.008	1.003-1.030
Sugar (mmol/L)	NG	NG	28	<2.8
Blood (ery/ul)	0.3	0.3	0.3	<0.3
Protein(g/L)	3.5	0.3	0.3	<0.1
TPU (g/d)	1.9	0.268	0.193	<0.14
RBC—Sediment (/ul)	70	18	3	0-18
WBC—Sediment (/ul)	24	21	29	0-23
COND—Sediment (Ms/cm)	28	8	6	15.1-27
Cast- Sediment(/ul)	2.08	0.91	0.62	0-2.5
B-J protein	NEG	NEG	NEG	NEG
Blood chemistry tests				
HGB(g/L)	141	96	105	115-148
WBC (10 ⁹ /L)	8.95	8.42	7.63	3.89-9.93
Eosinophils (%)	2.80%	3.20%	3.50%	6-Jan
Neutrophils (%)	60.10%	73%	65.60%	44-72
TP (g/L)	49.9	82.5	80.6	66-87
Alb (g/L)	28.6	40.5	40.8	35-52
UA (mmol/L)	212.4	314.1	199.1	142.8-339.2
Urea nitrogen(mmol/L)	3.6	13.6	5.4	2.76-8.07
Creatinine(mmol/L)	48	337	215	44-80
TC (mmol/L)	8.58	3.72	3.34	<5.2
ALT (IU/L)	8.3	32	2.7	0-33
AST (IU/L)	14.6	25	13.9	0-32
CRP (mg/L)	0.35	27.3	25.58	<5
ANA	1:100	1:320	1:320	<1:100
Anti-GBM antibody	-	-	-	-
PR3-ANCA (RU/ml)	-	-	-	-
MPO-ANCA (RU/ml)	-	-	-	-
PLA2R antibody (RU/ml)	48.12	-	-	<15
Total IgE (IU/mL)	NA	2486	NA	0-100
SARS-CoV-2-IgG (S-CO)	-	-	±	0-1
Kidney biopsy	MN	ATIN	ATIN	-

TPU: Total Protein Urinary; WBC: White Blood Cell; HGB: Hemoglobin; B-J protein: Bence-Jones Protein; ANA: Anti-Nuclear Antibody; TC: Total Cholesterol; ALT: Alanine Aminotransferase; AST: Aspartate Aminotransferase; CRP: C-Reactive Protein; TP: Total Protein; Alb: Albumin; GBM: Glomerular Basement Membrane; PLA-2R: Anti-Phospholipase A2 Receptor Antibody; UA: Uric Acid; ANCA: Anti-Neutrophil Cytoplasmic Antibodies; MN: Membranous Nephropathy; ATIN: Acute Tubulo-Interstitial

as a reference for other physicians that may face similar situation. To the best of our knowledge, this is the first report of ATIN following inactivated COVID-19 vaccination. Even though vaccine associated adverse reactions have been reported from time to time, the vital role of vaccines in containing the COVID-19 pandemic is unwavering.

Declaration

Statement of Ethics

Written informed consent was obtained from the patients for publication of this case report and any accompanying images.

Author contributions

YZ, LZ, PP in study conception, data collection and drafting the manuscript.

GW, PP provided clinical care and critical revision of the manuscript.

JG analyzed the pathology and provided the images.

All authors have read and approved the final manuscript.

References

1. WHO Coronavirus (COVID-19) dashboard.
2. Borobia AM, Carcas AJ, Pérez-Olmeda M, Castaño L, Bertran MJ, García-Pérez J, et al. Immunogenicity and reactogenicity of BNT162b2 booster in ChAdOx1-S-primed participants (CombiVacS): A multicentre, open-label, randomised, controlled, phase 2 trial. *The Lancet*. 2021;398(10295):121-30.
3. Maron DF. 'Wet markets' launched the coronavirus. Here's what you need to know. *Animals*. 2020.

4. COVID-19 vaccine tracker and landscape. 2021.
5. Izzedine H, Bonilla M, Jhaveri KD. Nephrotic syndrome and vasculitis following SARS-CoV-2 vaccine: True association or circumstantial? *Nephrol Dial Transplant*. 2021;36(9):1565-9.
6. Da Y, Goh GH, Khatri P. A case of membranous nephropathy following Pfizer-BioNTech mRNA vaccination against COVID-19. *Kidney Int*. 2021;100(4):938-9.
7. Bomback AS, Kudose S, D'Agati VD. *De novo* and relapsing glomerular diseases after COVID-19 vaccination: What do we know so far? *Am J Kidney Dis*. 2021;78(4):477-80.
8. Czerlau C, Bocchi F, Saganas C, Vogt B. Acute interstitial nephritis after mRNA-based vaccination. *Clin Kidney J*. 2021;15(1):174-6.
9. Gutiérrez S, Dotto B, Petiti JP, De Paul AL, Dionisio de Cabalier ME, Torres AI, et al. Minimal change disease following influenza vaccination and acute renal failure: Just a coincidence? *Nefrologia*. 2012;32(3):414-5.
10. Banerjee S, Dissanayake PV, Abeyagunawardena AS. Vaccinations in children on immunosuppressive medications for renal disease. *Pediatr Nephrol*. 2016;31(9):1437-48.
11. Jeffs LS, Nitschke J, Tervaert JWC, Peh CA, Hurtado PR. Viral RNA in the influenza vaccine may have contributed to the development of ANCA-associated vasculitis in a patient following immunisation. *Clin Rheumatol*. 2016;35(4):943-51.
12. Ella R, Reddy S, Jogdand H, Sarangi V, Ganneru B, Prasad S, et al. Safety and immunogenicity of an inactivated SARS-CoV-2 vaccine, BBV152: Interim results from a double-blind, randomised, multicentre, phase 2 trial, and 3-month follow-up of a double-blind, randomised phase 1 trial. *Lancet Infect Dis*. 2021;21(7):950-61.
13. Wu Z, Hu Y, Xu M, Chen Z, Yang W, Jiang Z, et al. Safety, tolerability, and immunogenicity of an inactivated SARS-CoV-2 vaccine (CoronaVac) in healthy adults aged 60 years and older: A randomised, double-blind, placebo-controlled, phase 1/2 clinical trial. *Lancet Infect Dis*. 2021;21(6):803-12.
14. Li NL, Coates PT, Rovin BH. COVID-19 vaccination followed by activation of glomerular diseases: does association equal causation? *Kidney Int*. 2021;100(5):959-65.
15. Dardalhon V, Korn T, Kuchroo VK, Anderson AC. Role of Th1 and Th17 cells in organ-specific autoimmunity. *J Autoimmun*. 2008;31(3):252-6.