



## Transient ST-Segment Elevation in the Context of MINOCA: A Case Report

Christoph C Kaufmann<sup>\*</sup>, Michael Nürnberg<sup>1</sup> and Kurt Huber<sup>1,2</sup>

<sup>1</sup>Department of Cardiology and Intensive Care Medicine, Wilhelminen Hospital, Austria

<sup>2</sup>Department of Cardiology, Sigmund Freud University, Austria

### Abstract

We present a case report of a patient with acute chest pain and transient ST-segment elevation. Emergency coronary angiography excluded significant coronary artery obstruction and hence the tentative diagnosis of Myocardial Infarction with Non Obstructive Coronary Arteries (MINOCA) was made. The following diagnostic work-up highlights the importance of a standardized approach to patients with MINOCA.

**Keywords:** Chest pain; Acute coronary syndrome; Coronary angiography; MR sequences

### Abbreviations

ECG: Electro Cardio Gram; IVS: Inter Ventricular Septum; IVUS: Intra Vascular Ultra Sound; LAD: Left Anterior Descending Artery; LVEDD: LV End Diastolic Diameter; MINOCA: Myocardial Infarction with Non Obstructive Coronary Arteries; MRI: Magnetic Resonance Imaging; OCT: Optical Coherence Tomography; RCA: Right Coronary Artery; STEMI: ST Elevation Myocardial Infarction

### Learning Objectives

- To understand the importance of a standardized approach to establish the diagnosis of MINOCA.
- To be able to identify the different etiologies of MINOCA and their respective management.

### OPEN ACCESS

#### \*Correspondence:

Christoph C Kaufmann, Department of Cardiology and Intensive Care Medicine, Wilhelminen Hospital, Montleartstrasse 37, A-1160 Vienna, Austria, Tel: +43-149150-2301; Fax: +43-149150-2309; E-mail: Christoph.Kaufmann@wienkav.at

**Received Date:** 11 Oct 2019

**Accepted Date:** 18 Nov 2019

**Published Date:** 22 Nov 2019

#### Citation:

Kaufmann CC, Nürnberg M, Huber K. Transient ST-Segment Elevation in the Context of MINOCA: A Case Report. *Clin Case Rep Int.* 2019; 3: 1126.

**Copyright** © 2019 Christoph C Kaufmann. This is an open access article distributed under the Creative Commons Attribution License, which permits unrestricted use, distribution, and reproduction in any medium, provided the original work is properly cited.

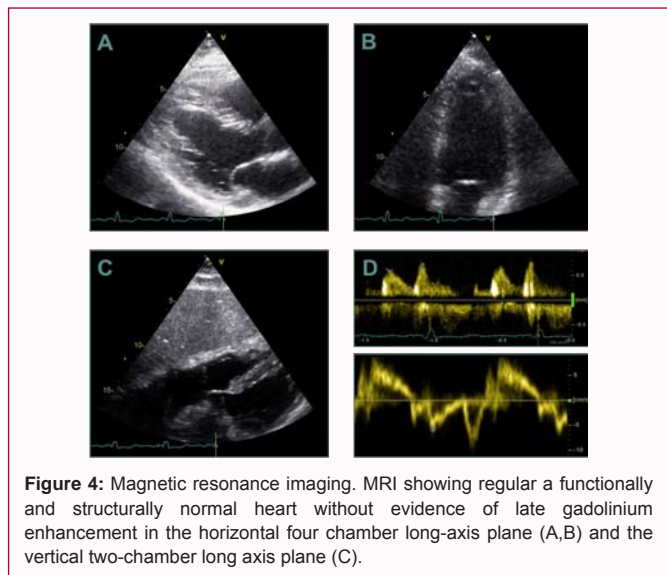
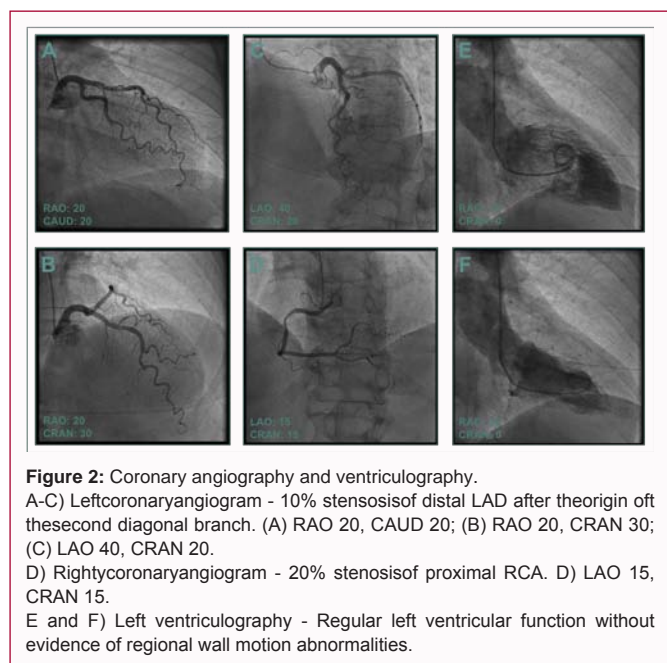
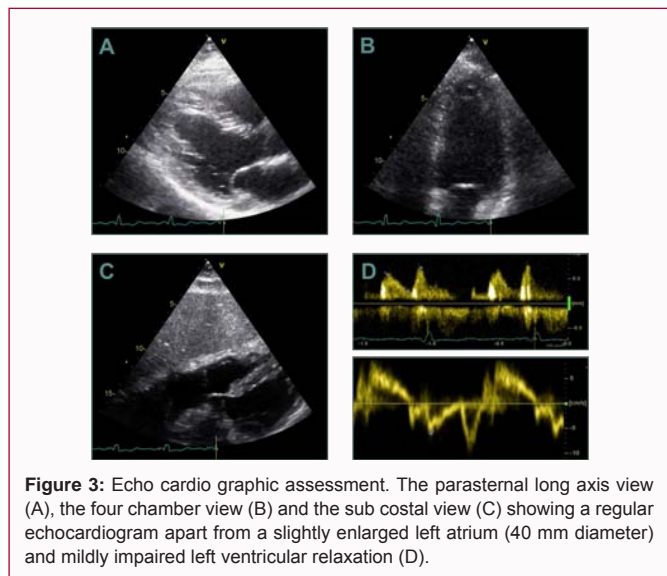
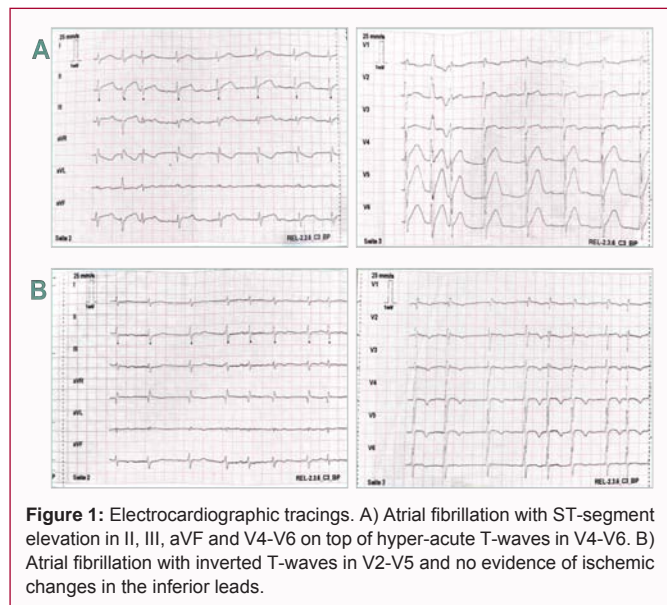
### History of Presentation and Past Medical History

A 59-year-old female patient experienced a sudden episode of heavy chest pain after work, upon which she called the emergency ambulance service. Except for a history of cervical syndrome and chronic lower back pain, not requiring medication, the patient was previously fit and well. Upon arrival of the emergency physician a 12-channel ECG was recorded (Figure 1A), which showed atrial fibrillation with inferior and antero lateral ST-segment elevation (II, III, aVF & V4-V6) on top of hyper-acute T-waves in the antero lateral leads (V4-V6). Accordingly, the physician contacted our coronary care unit for emergency coronary catheterization based on the tentative diagnosis of acute ST-Segment Elevation Myocardial Infarction (STEMI). The patient was loaded with 250 mg of intravenous Acetylsalicylic Acid (ASA) and 60 mg of oral prasugrel. Additionally, 5000 IE of unfractionated heparin and 80 mg of atorvastatin were administered on site. The transport to our hospital by helicopter was uneventful and according to protocol. The fulminant ST-segment changes in the initial ECG, however, were no longer visible on follow-up ECG (Figure 1B). Instead, inverted T-waves were recorded in leads V2-V5 without evidence of significant ischemia in the inferior leads.

### Investigations

Emergency coronary angiography (Figure 2) (Videos 1-8) revealed non-significant coronary artery disease with 20% proximal Right Coronary Artery (RCA) stenosis and 10% distal Left Anterior Descending (LAD) stenosis after the origin of the second diagonal branch. Hence, excluding a type I myocardial infarction. Left ventriculography was unremarkable with preserved ejection fraction and no signs of regional wall motion abnormalities or a Takotsubo-like pattern.

The findings of left ventriculography were confirmed by transthoracic echocardiography (Figure 3), which showed a virtually normal echocardiogram. The thickness of the Intra Ventricular Septum (IVS) was measured at 11 mm alongside a regular Left Ventricular End Diastolic Diameter



(LVEDD=46 mm) and preserved ejection fraction. The only pathological findings were a left ventricular diastolic relaxation abnormality ( $E/A=0.81$ ,  $E/e' = 9.67$ ) and a slightly enlarged left atrium (Left atrium =40 mm). Cardiac Magnetic Resonance Imaging (MRI) (Figure 4) revealed a structurally and functionally normal heart without evidence of fibrosis, edema or late gadolinium enhancement on T1- and T2-mapping. In-hospital ECG monitoring showed stable sinus rhythm without episodes of atrial or ventricular arrhythmias. The isolated episode of atrial fibrillation on admission had no recurrence and was hence interpreted within the scope of the acute myocardial event without a need for long-term oral anticoagulation. Ambulatory twenty-four-hour electrocardiographic (Holter) monitoring confirmed normal sinus rhythm without any arrhythmic events.

**Management**

The case at hand presents a typical example of MINOCA of

unclassified origin. Significant coronary artery disease was excluded by emergency coronary angiography and extended non-invasive cardiac work-up revealed no signs of significant cardiac disease. While an additional invasive diagnostic work up is sometimes warranted, it is not always feasible. Upon recognition of non-significant coronary artery disease further diagnostics, including coronary imaging and acetylcholine provocation testing for vasospastic angina, had to be delayed due to the arrival of another acute STEMI. Repeat coronary angiography was denied by the patient for now. Hence, potential differential diagnosis includes vasospastic angina, coronary artery dissection, plaque rupture/erosion or thromboembolism. Upon 3-months follow-up the patient was fine and free of symptoms.

**Discussion**

MINOCA is a growing entity in the differential diagnosis of acute chest pain. At present, it occurs in approximately 5% to 6% of cases with acute myocardial infarction [1]. However, there is a large variability in its reported prevalence (up to 15% in selected studies), which may be attributed to the lack of a universal definition of the disease. The introduction of the Fourth Universal Definition of myocardial infarction finally offered specific diagnostic criteria

for MINOCA, which were revisited by a scientific statement paper from the American Heart Association (AHA) in 2019 [2]. The three key diagnostic criteria for MINOCA include the presence of acute myocardial infarction (a rise and fall pattern of troponin and clinical evidence of ischemia), non obstructive coronary arteries (including moderate coronary atherosclerotic stenosis of up to 50%) and the absence of an alternate diagnosis for the clinical presentation, such as sepsis, pulmonary embolism or myocarditis [3].

Coronary angiography is the main diagnostic tool in the initial workup of patients with chest pain and myocardial infarction. After exclusion of significant coronary artery stenosis, coronary vascular imaging and coronary function assessment should be performed. Intra Vascular Ultra Sound (IVUS) and Optical Coherence Tomography (OCT) allow visualization of plaque disruption, coronary thrombi or emboli and coronary artery dissection. Provocation testing with intracoronary acetylcholine may help to facilitate the diagnosis of coronary vasospasm [3]. While an acceptable level of safety has been reported recently for provocative testing, significant arrhythmic events occur in up to 6% of cases (including 3% ventricular arrhythmias) [4]. If coronary angiography remains inconclusive, left ventriculography should be performed to assess left ventricular function and look for wall motion abnormalities, resembling Takotsubo Syndrome or other cardiomyopathies [5].

The following non-invasive diagnostic work-up should include echo cardio graphic assessment as well as Magnetic Resonance Imaging (MRI) in most cases. While availability is still a concern in some regions, cardiac MRI has emerged as a key diagnostic tool in the evaluation of patients with MINOCA. Myocarditis and Takotsubo syndrome, which is rather its own entity than a part of MINOCA, are the most frequent conditions mimicking MINOCA and can be diagnosed by MRI based on specific late gadolinium enhancement patterns and imaging findings [6].

Management of MINOCA is diverse and should be individualized based on the specific etiology, such as calcium channel blockers for vasospastic angina, antianginal therapies for micro vascular dysfunction, anticoagulation for coronary embolism and cardio protective therapy in accordance with current AMI guidelines for plaque disruptions [3].

## Conclusion

MINOCA is an important differential diagnosis in the work-up of patients with acute myocardial infarction. A standardized diagnostic approach allows identification of a specific etiology with respective treatment in most cases.

## Acknowledgment

### Funding

The research was supported by the Ludwig Boltzmann Cluster for Cardiovascular Research, Vienna, and the Association for the Promotion of Research in Arteriosclerosis, Thrombosis and Vascular Biology (ATVB), Vienna.

### Consent

The author/s confirm that written consent for submission and publication of this case report including image(s) and associated text has been obtained from the patient in line with COPE guidance.

## References

1. Pasupathy S, Air T, Dreyer RP, Tavella R, Beltrame JF. Systematic review of patients presenting with suspected myocardial infarction and nonobstructive coronary arteries. *Circulation*. 2015;131(10):861-70.
2. Thygesen K, Alpert JS, Jaffe AS, Chaitman BR, Bax JJ, Morrow DA, et al. Fourth universal definition of myocardial infarction (2018). *Eur Heart J*. 2019;40(3):237-69.
3. Tamis-Holland JE, Jneid H, Reynolds HR, Agewall S, Brilakis ES, Brown TM, et al. Contemporary Diagnosis and Management of Patients with Myocardial Infarction in the Absence of Obstructive Coronary Artery Disease: A Scientific Statement from the American Heart Association. *Circulation*. 2019;139(18):e891-908.
4. Takagi Y, Yasuda S, Takahashi J, Tsunoda R, Ogata Y, Seki A, et al. Clinical implications of provocation tests for coronary artery spasm: safety, arrhythmic complications, and prognostic impact: multicentre registry study of the Japanese Coronary Spasm Association. *Eur Heart J*. 2013;34(4):258-67.
5. Ghadri JR, Wittstein IS, Prasad A, Sharkey S, Dote K, Akashi YJ, et al. International Expert Consensus Document on Takotsubo Syndrome (Part I): Clinical Characteristics, Diagnostic Criteria, and Pathophysiology. *Eur Heart J*. 2018;39(22):2032-46.
6. Pathik B, Raman B, Mohd Amin NH, Mahadavan D, Rajendran S, McGavigan AD, et al. Troponin-positive chest pain with unobstructed coronary arteries: incremental diagnostic value of cardiovascular magnetic resonance imaging. *Eur Heart J Cardiovasc Imaging*. 2016;17(10):1146-52.