



## Upadacitinib: One More Option in the Treatment of Patients with Rheumatoid Arthritis and Crohn's Disease

Del Giudice A<sup>1\*</sup>, Giuggioli D<sup>2,3</sup>, Bertani A<sup>4</sup> and Sandri G<sup>2,3</sup>

<sup>1</sup>Rheumatology Unit, University of Modena and Reggio Emilia, Italy

<sup>2</sup>Rheumatology Unit, Azienda Ospedaliero-Universitaria Policlinico di Modena, Italy

<sup>3</sup>Department of Medical and Surgical Sciences for Children and Adults, University of Modena and Reggio Emilia, Italy

<sup>4</sup>Gastroenterology Unit, Azienda Ospedaliero-Universitaria Policlinico di Modena, Italy

### Abstract

Arthritis and IBD are conditions that can occur in the same patient simultaneously. The complexity in managing these cases lies in detecting the signs and symptoms that point to the onset of the disease at an early stage, and in choosing an appropriate course of treatment to control the joint and intestinal aspects at the same time. In recent times, a new class of drugs has been added to the treatment options: JAK inhibitors (JAKi), of which Upadacitinib is one. Being able to manage and follow up with these patients in joint gastro-rheumatology outpatient clinics, where professionals from both disciplines are able to follow these cases appropriately, avoiding delays in diagnosis and treatment, is also important.

### Introduction

Arthritis is one of the most frequent extra-intestinal complications in IBD patients. The majority of them have peripheral oligoarthritis, and the most affected are the knees, the Coxofemoral joint, wrists and elbows. A smaller number have symmetrical polyarthritis, with a presentation similar to RA. Arthritis and intestinal disease do not occur or flare up at the same time, but are independent of each other [1].

The difficulties in the management of these patients lie in the choice of the most suitable treatment to best control both diseases. In clinical practice, only a small proportion of patients with IBD and joint symptoms are followed up in an appropriate way in a joint gastro-rheumatology outpatient clinic. This leads to neither aspect being considered in a simultaneous manner, resulting in unsuitable treatments, which do not adequately address the two inflammatory diseases, thereby impacting on the patient's quality of life. This not only delays diagnosis and treatment, but also underestimates the prevalence of enteropathic arthritis [2-4].

### Case Presentation

In July 2020, a 60-year-old woman was referred to the Rheumatology Outpatient Clinic at the Polyclinic of Modena for the first time due to worsening joint symptoms after a prolonged period of being off the maintenance treatment.

In her medical history, she had been diagnosed with Rheumatoid Arthritis (RA) in 2005, with positive Rheumatoid Factor and anti-CCP Ab, and thereafter Crohn's Disease (CD) diagnosed in 2009. The latter was an aggressive form with a challenging progression, which led the patient to undergo a number of surgical colonic resections over the years.

Since the diagnosis of RA, and for the years that followed, the patient was on basic medication, initially with DMARDs (Disease-Modifying Antirheumatic Drugs) and later replaced with anti TNF- $\alpha$ , discontinued and then changed over time due to the onset of side effects or loss of efficacy (Table 1).

Following surgery for perforation of a laparocoele, the patient decided on her own initiative to discontinue maintenance treatment, taking only Mesalazine.

At the time of admission, the patient reported taking methylprednisolone (8-16 mg/day) to treat an acute arthritis attack.

### OPEN ACCESS

#### \*Correspondence:

Adele Del Giudice, Rheumatology Unit, University of Modena and Reggio Emilia, Modena, Italy, Tel: 3347781152;

Received Date: 20 Mar 2024

Accepted Date: 04 Apr 2024

Published Date: 09 Apr 2024

#### Citation:

Del Giudice A, Giuggioli D, Bertani A, Sandri G. Upadacitinib: One More Option in the Treatment of Patients with Rheumatoid Arthritis and Crohn's Disease. *Clin Case Rep Int.* 2024; 8: 1677.

Copyright © 2024 Del Giudice A. This is an open access article distributed under the Creative Commons Attribution License, which permits unrestricted use, distribution, and reproduction in any medium, provided the original work is properly cited.

**Table 1:** DMARDs and later replaced with anti TNF- $\alpha$ , discontinued and then changed over time due to the onset of side effects or loss of efficacy.

TREATMENT	TIME FRAME	REASON FOR DISCONTINUATION
Etanercept	2007–2009	No intestinal control
Infliximab + Leflunomide	2009–2013	Loss of efficacy
Adalimumab	2013–2017	Surgical intervention

At the time the data were recorded: 2 painful joints (wrists) and 4 swollen joints (wrists and knees), increased inflammation markers (ESR 42 mm/h and CRP 1.4 mg/dl), pain reported 8/10 on the VAS scale, DAS-28 5.1 (high disease activity) and Disability Index (HAQ) of 3 (full disability).

Apart from RA and CD, the patient had no other comorbidities or risk factors.

A decision was made to continue methylprednisolone, Mesalazine 1200 mg and to introduce Tapentadol 100 mg/day and Pregabalin 150 mg/day for pain. Finally, further blood tests were requested.

At the September follow-up, the clinical picture did not appear to be in remission. The painful and swollen joints persisted in terms of quantity and location and the inflammatory markers were further increased (ESR 106 mm/h, CRP 7 mg/dl). DAS-28 (5.74), and pain unaltered.

Screening tests (Quantiferon, HIV, hepatotropic viruses) were negative.

The only opportunity to improve the condition of the patient was to reintroduce maintenance therapy.

The difficulties that arose in the management of this case were related to the fact that a balance had to be created and maintained on the joint and intestinal side, using a drug other than anti-TNF $\alpha$ .

After consulting with experienced IBD gastroenterologists, it was decided to try introducing Upadacitinib as a maintenance treatment.

As a result, Upadacitinib 15 mg 1 tablet per day was introduced in October 2020, always combined with methylprednisolone 8 mg, until the next follow-up.

At the next visit, the situation had improved markedly: Only one joint remained puffy and swollen, the inflammation markers were falling (ESR 35 mm/h CRP 0.4 mg/dl). Pain reported VAS 2/10, DAS-28 3.6 (moderate disease activity) and HAQ 2.25. No reported flare-ups of intestinal disease were reported.

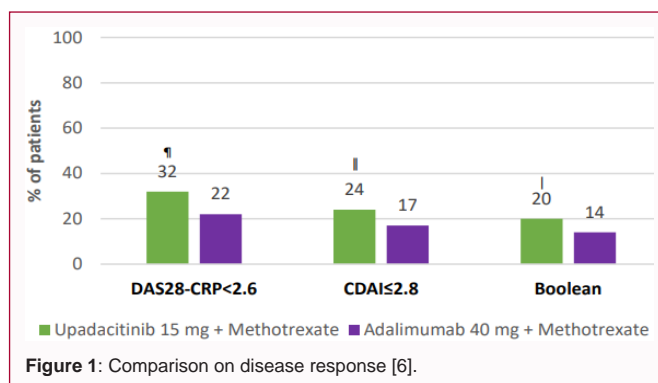
As the patient's symptoms were generally in good control, it was decided to start corticosteroid withdrawal, analgesic treatment with only Pregabalin 150 mg and continue with Mesalazine and Upadacitinib, as it was well tolerated with no adverse events.

## Discussion

Among the possible lines of treatment for inflammatory diseases, small molecule inhibitors of Janus Kinases (JAK), such as Upadacitinib, have recently started to be used.

JAK kinases are non-receptor tyrosine kinases that activate the signals mediated through the JAK-STAT metabolic pathway, which is essential for inducing and maintaining the inflammatory-immune response.

Specifically, Upadacitinib is a partially selective inhibitor for JAK1 tyrosine kinases, the isoform mainly involved in inflammatory



and innate immune responses. Studies have shown that inhibition of this Janus kinase, and therefore of the pathway it activates, would lead to the improvement of symptoms and signs of various immune-mediated diseases such as rheumatoid arthritis, psoriatic arthritis, ankylosing spondylitis, atopic dermatitis and chronic intestinal diseases [5].

Studies and reviews carried out in recent years have demonstrated the efficacy, especially in the long term, of the use of Upadacitinib in rheumatology patients in terms of clinical response and disease remission irrespective of the type of population analyzed (naive patients or those with previous Methotrexate (MTX) or biological failure). In one study, the combination of Upadacitinib and MTX was shown to be superior to Adalimumab and MTX in patients with an inadequate response to MTX alone (Figure 1) [6,7].

A further study compared Upadacitinib and Abatacept on the efficacy of maintaining remission in patients with RA who were unresponsive to therapy with DMARDs or other biological drugs. Upadacitinib proved to be the better of the two (30% in remission vs. 13%), although unfortunately there were no side effects associated with it [8]. Studies on the safety of Upadacitinib, both 15 mg and 30 mg, compared to Adalimumab and MTX have been carried out on this point. The most frequent adverse effects were upper respiratory tract infections and urinary tract infections with both JAKi dosages, in addition to an increase in CPK with Upadacitinib 30 mg. The highest incidence of major adverse events was seen with Upadacitinib 30 mg, while the incidence of serious side effects was similar for Upadacitinib and Adalimumab. The most alarming side effect is that of a major cardiovascular event, since JAKi have a pro-thrombotic effect. However, studies have shown that none of the subclasses of disease-modifying drugs (JAKi, TNF inhibitors and interleukin inhibitors) significantly influenced the likelihood of the occurrence of Major Adverse Cardiovascular Events (MACE). The same applies to the occurrence of venous thromboembolic events [6,9,10].

With regard to CD, Upadacitinib (45 mg) has been shown to be one of the best drugs for the remission of this disease in both patients who have and those who have never had biological therapy, together with Infliximab and Rizankizumab. On the maintenance front, however, Upadacitinib (15 mg) was the best, followed by

Adalimumab and Infliximab [11,12].

## Conclusion

Arthritis and CD are two conditions that are often simultaneously found in the same patient. As both are chronic diseases, the aim of the underlying treatment is to achieve remission of the disease (from a clinical, laboratory and endoscopic point of view) and to maintain this condition. Consequently, it is necessary to find and maintain the right balance between the two components, the joint and the intestinal components. Corticosteroids, immunosuppressants, anti-inflammatories and biologicals fulfil this purpose, but the choice of which ones to use is the real challenge. The problems to be addressed are mainly:

- The non-tolerability of the drug
- The efficacy of a biological drug on one component, but not the other
- The loss of efficacy over time

The fact that JAKi has been shown to be effective in the treatment of enteropathic arthritis has certainly added a therapeutic opportunity for these patients. In the clinical case described, Upadacitinib was used as an example in a history of repeated failures with first- and second-line drugs.

Another central aspect is the importance of multidisciplinary management of these patients. The opportunity for several specialists, rheumatologists and gastroenterologists, with expertise in spondyloarthritis and IBD, to work together to achieve a faster diagnosis and provide a tailor-made treatment plan for the patient. Using their knowledge and clinical experience, they are able to focus on the 'red flags' that highlight the coexistence of these two chronic inflammatory diseases, reducing delays in diagnosis, which have major consequences: Uncontrolled disease progression, long-term, permanent and disabling complications that reduce the patients' quality of life. Early diagnosis and treatment also lead to a better primary response of the patient to treatment, with benefits for both the patient and the treating specialists [2-4].

## References

1. Disease IB. *Advances in IBD*. 2012;8:327-9.
2. Maria ML, Benfaremo D, Bendia E, Bolognini L, Fava G, Marini F, et al. Clinical and patient reported outcomes of the multidisciplinary management in patients with inflammatory bowel disease-associated spondylarthritis. *Eur J Intern Med*. 2019;64:76-84.
3. Lorenzetti R, Scolieri P, Guarini A, Marini F De, Zullo A, Hassan C, et al. Integrated gastroenterology and rheumatology ambulatory: An innovative approach for enteropathy spondylarthritis early diagnosis. *Ann I<sup>st</sup> Super Sanita*. 2019;55:246-8.
4. Gudu T, Jadon DR. Multidisciplinary working in the management of axial and peripheral spondyloarthritis. *Ther Adv Musculoskelet Dis*. 2020;12.
5. Traves PG, Murray B, Campigotto F, Galien R, Meng A, Di Paolo JA, et al. JAK selectivity and the implications for clinical inhibition of pharmacodynamic cytokine signaling by filgotinib, Upadacitinib, tofacitinib and baricitinib. *Ann Rheum Dis*. 2021;80:865-75.
6. Sanmartí R, Corominas H. Upadacitinib for patients with rheumatoid arthritis: A comprehensive review. *J Clin Med*. 2023;12:1734.
7. Burmester GR, Cohen SB, Winthrop KL, Nash P, Irvine AD, Deodhar A, et al. Safety profile of Upadacitinib over 15,000 patient-years across rheumatoid arthritis, psoriatic arthritis, ankylosing spondylitis and atopic dermatitis. *RMD Open*. 2023;9:e002735.
8. Rischmueller M, Rubbert-Roth A, Enejosa J, Pangan AL, Haraoui B, Khan N, et al. Trial of Upadacitinib or abatacept in rheumatoid arthritis. *N Eng J Med*. 2020;383:1511-21.
9. Fleischmann R, Haraoui B, Buch MH, Gold D, Sawyerr G, Shi H, et al. Pos0086 analysis of disease activity measures in the context of a methotrexate withdrawal study among patients with rheumatoid arthritis treated with tofacitinib 11 Mg once daily + methotrexate: Post hoc analysis of data from oral shift. *Ann Rheum Dis*. 2021;80:251.
10. Thanigaimani S, Phie J, Krishna S, Moxon J, Golledge J. Effect of disease modifying anti-rheumatic drugs on major cardiovascular events: a meta-analysis of randomized controlled trials. *Sci Rep*. 2021;11:12378.
11. Barberio B, Gracie DJ, Black CJ, Ford AC. Efficacy of biological therapies and small molecules in induction and maintenance of remission in luminal Crohn's disease: Systematic review and network meta-analysis. *Gut*. 2023;72:264-74.
12. Loftus EV, Panés J, Lacerda AP, Peyrin-Biroulet L, D'Haens G, Panaccione R, et al. Upadacitinib induction and maintenance therapy for Crohn's disease. *N Engl J Med*. 2023;388:1966-80.